

CRANIOSYNOSTOSIS

- Pathological condition that results from premature fusion of one or more sutures in the cranial vault;
- Associated with a deformity of the vault and cranial base.

Development

Bones of the cranium

- The skull base and the calvarial vault
- Growth of skull bones
Expanding growth of the brain.

Brain Growth

- At term has nearly 40 percent of his or her adult brain volume,
- And this increases to 80 percent by three years of age.
- Continues to grow until the age of 12 yrs

The cranium

- At term is 40 percent of adult size;
- By seven years, this increases to 90 percent.
- *Sun PP, Persing JA. Craniosynostosis. In: Albright AL, Pollack IF, Adelson PD, eds. Principles and practice of pediatric neurosurgery. New York: Thieme Medical, 1999:219-42.*

Timing of Closure of Sutures and Fontanelles

<i>Type of suture/fontanelle</i>	<i>Time to closure</i>
Metopic suture	Nine months to two years (may persist into adulthood)
Coronal, sagittal, lambdoid sutures	40 years
Anterior fontanelle	Nine to 18 months
Posterior fontanelle	Three to six months
Anterolateral fontanelle	Three months
Posterolateral fontanelle	Two years

Adapted with permission from Aviv Ri, Rodger E Hall CM. Craniosynostosis. Clin Radiol 2002;57:94.

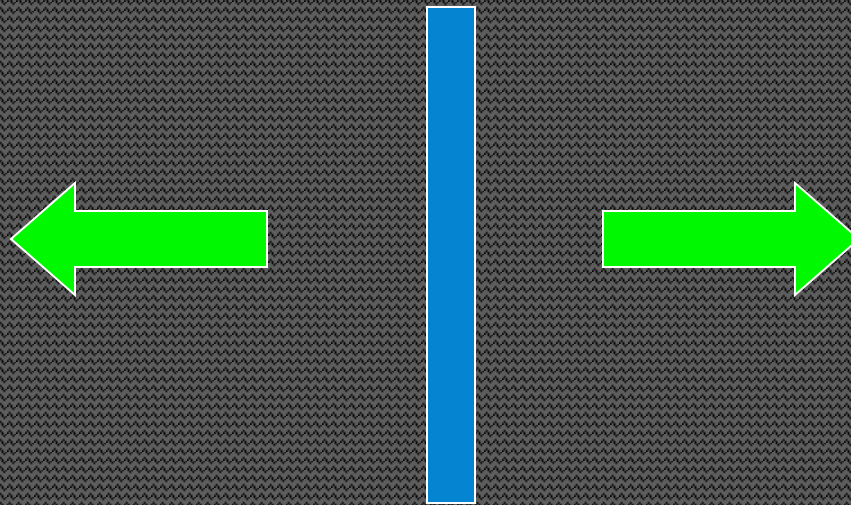
Mature suture closure occurs by 12 years of age, but completion continues into the third decade of life and beyond.

HISTORY AND PATHOGENESIS

- **Otto** (1830) coined the term craniosynostosis
- **Stahl** and **Hyrtl** noticed that premature closure of the cranial vault sutures leads to an abnormal skull shape.
- In **1851**, **Virchow** described how skull growth is restricted to a plane perpendicular to the affected, prematurely fused suture and is enhanced in a plane parallel to it.

Suture Growth

- Sutures allow growth perpendicular to them
 - Growth at suture lines related to brain growth



- Virchow - classify the different types of skull deformity
- Van der Klaauw, in 1946, and Moss, in 1959.

Cranial base source of abnormal physical stress leading to dural abnormalities that yielded premature sutural fusion

- Animal studies

The cranial vault abnormalities typical of synostosis can be produced with experimental fusion of developing cranial vault sutures.

- 1. *Persing JA, Babler WJ, Jane JA, et al. Experimental unilateral coronal synostosis in rabbits. Plast Reconstr Surg. 1986;77:369–376.*

- Marsh and Vannier –

Following cranioplasty in patients with individual suture craniosynostosis in which surgery altered only the cranial vault structure, previously developed cranial base abnormalities were ameliorated

Marsh JL, Vannier MW. Cranial base changes following surgical treatment of craniosynostosis. *Cleft Palate J.* 1986;23(suppl. 1):9.

- **L.C Lane** First surgical procedure to release stenosed suture
- **Lannelogue-1890** performed bilateral strip craniectomies
- **Tessier** - Father of modern craniofacial Surgery.

First to attempt major surgical procedures on the craniofacial skeleton.

Incidence

- One per 1,800 to 2,200 live births
 - Males - Sagittal and metopic stenosis
 - Females - Coronal
-
- Reefhuis J, Honein MA, Shaw GM, Romitti PA. Fertility treatments and craniosynostosis: California, Georgia, and Iowa, 1993-1997. *Pediatrics* 2003;111(5 pt 2):1163-6.

Theories of Cranoisynostosis

- **Sommering(1839)**– Noted that bone growth in skull primarily occurs at suture line and if it prematurely fused, an abnormal skull shape developed and skull growth restricted.
- **Virchow(1821) and Otto(1830)**- Similar observation were made and they noted restriction of growth adjacent to suture and compensatory growth occurred at elsewhere in skull to accommodate growing brain .
- **Jane JA:** The major cause of the global cranial deformity was compensatory overgrowth at adjacent sutures.

Theories of Craniosynostosis

- **Moss(1959)** – Described functional matrix theory. According to this theory cranial base abnormality was the primary pathological process and cranial vault suture abnormality was secondary as cranial base mature embryologically before cranial vault.
- **Persson (1979)** – Cranial vault suture pathology may be primary in the development of synostosis leading to cranial base and facial deformity.
- **Marsh and Vannier(1986)**- Following cranioplasty in patients with individual suture craniosynostosis, surgery altered only the cranial vault structure, the previously developed cranial base abnormalities were not ameliorated .

Familial Non syndromic Craniosynostosis

- Affects 2 to 6 percent with sagittal synostosis
- 8 to 14 percent of infants with coronal synostosis
- Autosomal dominant disorder.

Sun PP, Persing JA. Craniosynostosis. In: Albright

AL, Pollack IF, Adelson PD, eds. Principles and practice of pediatric neurosurgery. New York: Thieme Medical, 1999:219-42.

Syndromic craniosynostosis

- Is less common (20 percent)
 - More than 150 syndromes with craniosynostosis have been identified.
 - Multiple sutures are involved.
 - Autosomal dominant
-
- *Cohen MM Jr. Craniosynostoses: phenotypic/molecular correlations. Am J Med Genet 1995;56:334-9.*

Etiology

- Unknown
- Sporadic in most instances

Risk factors

- White maternal race
- Advanced maternal age
- Male infant sex
- Maternal smoking
- Residence at high altitude
- Nitrosatable drugs (e.g. nitrofurantoin, chlordiazepoxide, chlorpheniramine),
- Certain paternal occupations (e.g. agriculture and forestry, mechanics, repairmen)
- Fertility treatments.

Alderman BW et al. An epidemiologic study of craniosynostosis: risk indicators for the occurrence of craniosynostosis in Colorado.
Am J Epidemiol 1988;128:431-8.

Pathophysiology

- Cranial sutures - fibrous joints
- Abnormal osteoblastic activity –
observed in cultures of synostotic bone
- Decreased growth rate
- Decreased alkaline phosphatase production
- Increased levels of osteocalcin
 - platelet-derived growth factor
 - epidermal growth factor .

- Fibroblast growth factor and fibroblast growth factor receptor (FGFR) regulate fetal osteogenic growth
- Expressed in cranial sutures in early fetal life.

Mutations in the gene coding for

- **FGFR₁** → Pfeiffer's disease.
- **FGFR₂** → Apert's syndrome and Crouzon's disease.

TABLE 2

Classification of Craniosynostosis

Primary

Simple

Nonsyndromic: sagittal, coronal, metopic, lambdoid

Compound

Nonsyndromic: bicoronal

Syndromic: Crouzon's disease, Apert's syndrome, Pfeiffer's disease, Saethre-Chotzen syndrome

Secondary

Metabolic disorders (e.g., hyperthyroidism)

Malformations (e.g., holoprosencephaly, microcephaly, shunted hydrocephalus, encephalocele)

Exposure of fetus (e.g., valproic acid, phenytoin)

Mucopolysaccharidosis (e.g., Hurler's syndrome, Morquio's syndrome)

Adapted with permission from Sun PR, Persing JA.

Craniosynostosis. In: Albright AL, Pollack IE, Adelson

PD, eds. Principles and practice of pediatric neurosurgery. New York: Thieme Medical, 1999:221, and

Aviv RI, Rodger E, Hall CM. Craniosynostosis. Clin Radiol 2002;57:94.

Types

- Scaphocephaly (Sagittal synostosis)

Derived from the Greek words *scaphos*, meaning *boat*, and *kephali*, meaning *head*.

Most common 45-50%

Plagiocephaly

- Greek word *plagios*, meaning *oblique or sloping*, and corresponds to *unilateral coronal synostosis*.
- 10-20%

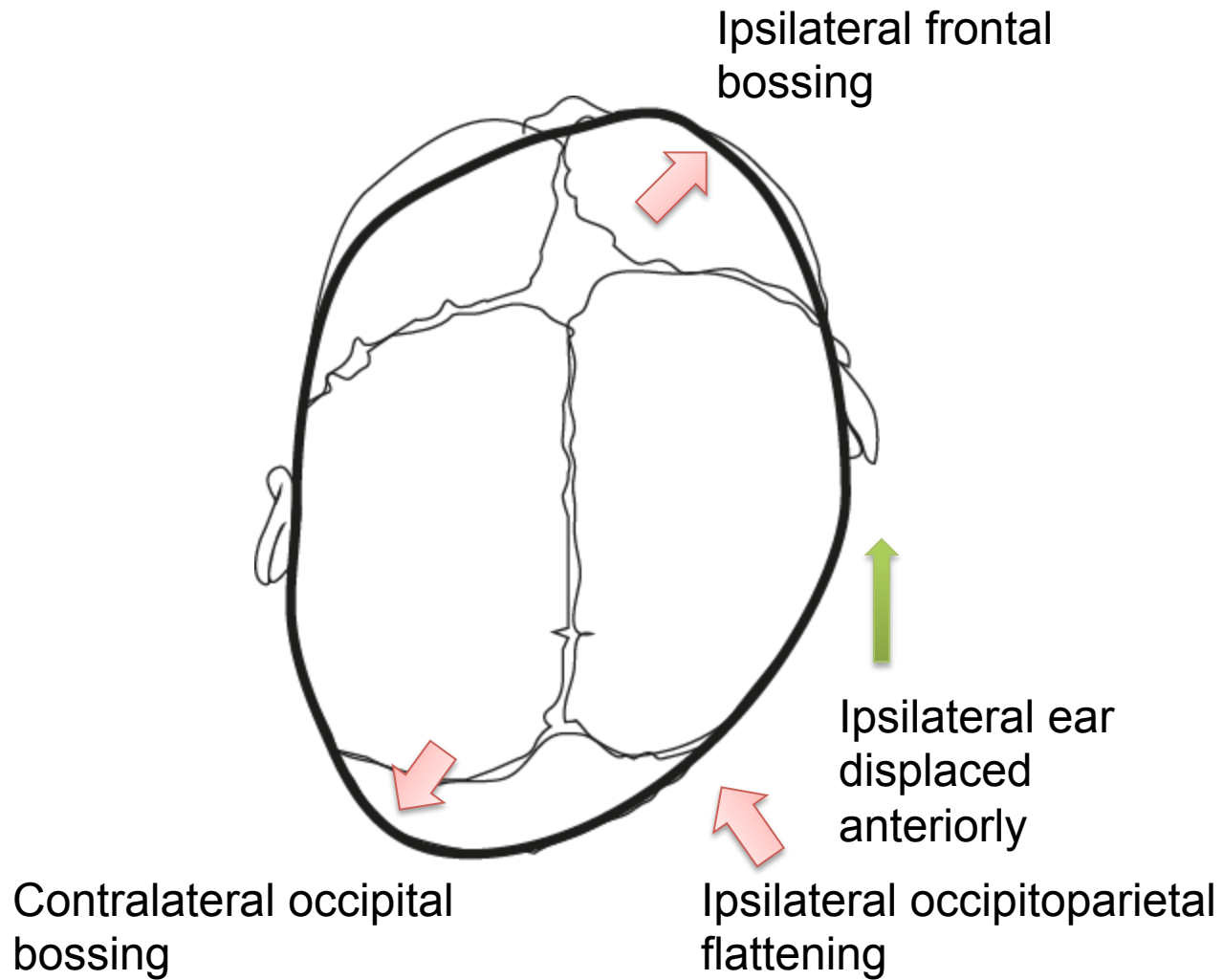
- Posterior plagiocephaly corresponds to *lambdoid synostosis*.
- 1.3%

Left coronal synostosis

Asymmetry of the orbits

Widened palpebral fissure on the left

Superiorly displaced left eyebrow.



Trigonocephaly

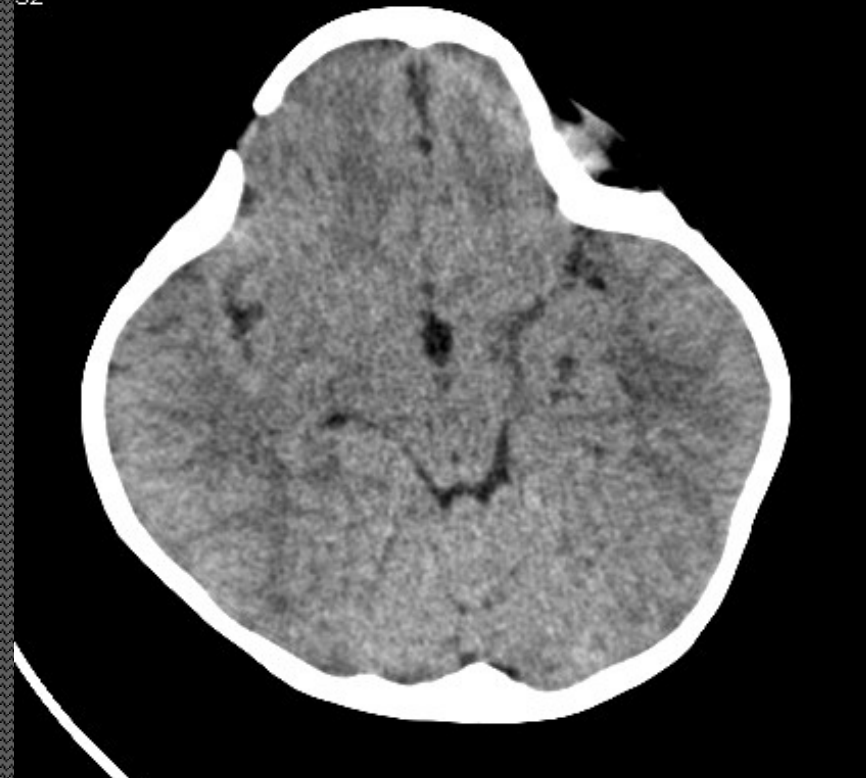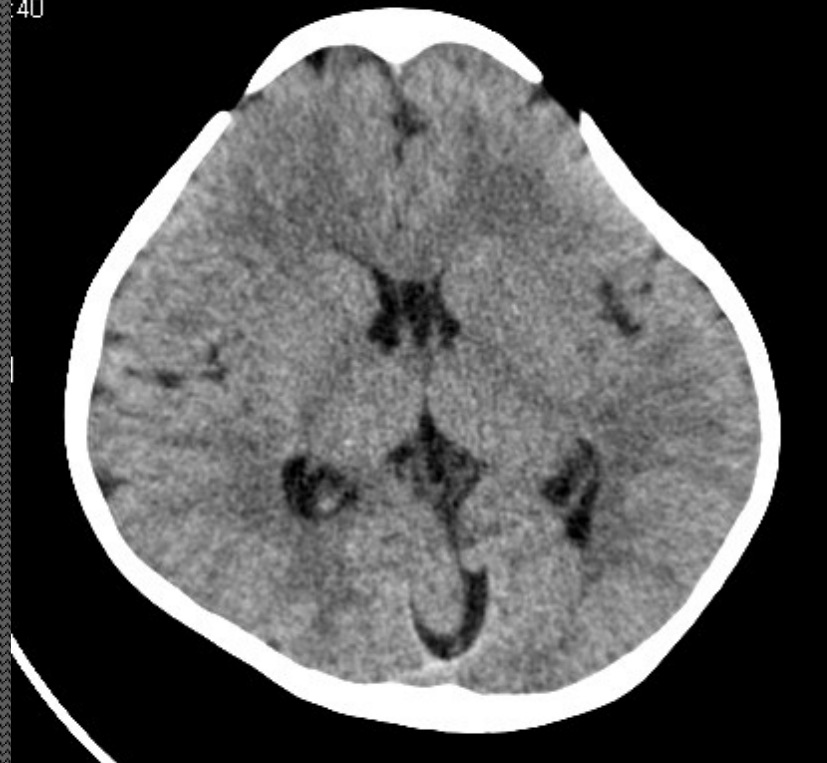- Derived from the Greek word *trigonos*, meaning *triangular*
- *Metopic synostosis.*
- 5 → 10% incidence

ation:
:3
:40

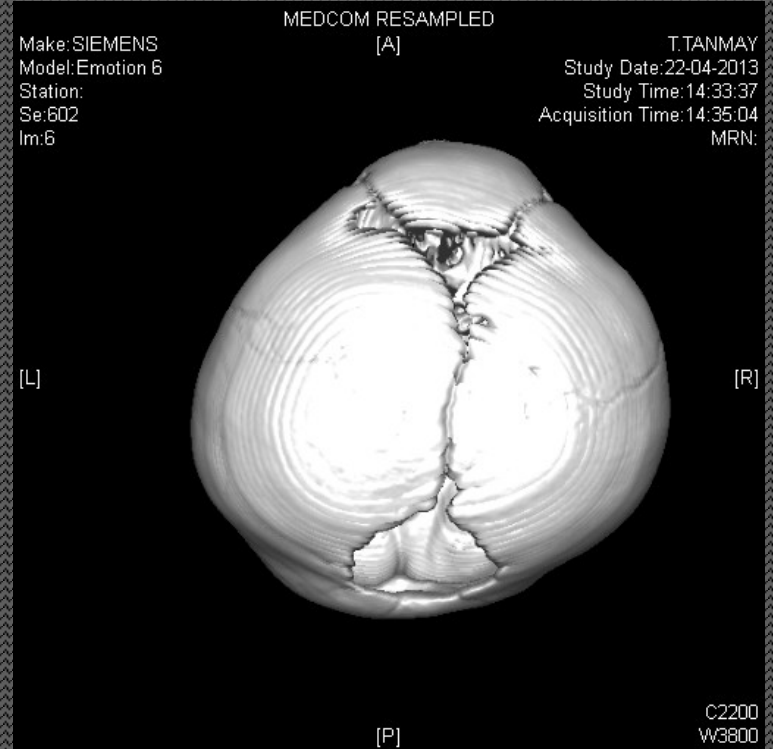
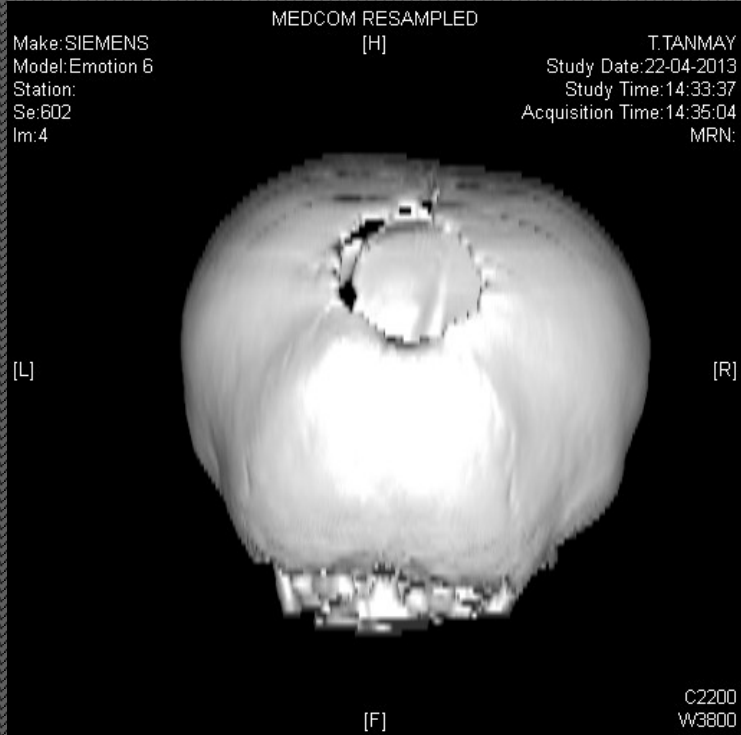
Study
Acquisition

3
32

Acquisition Time



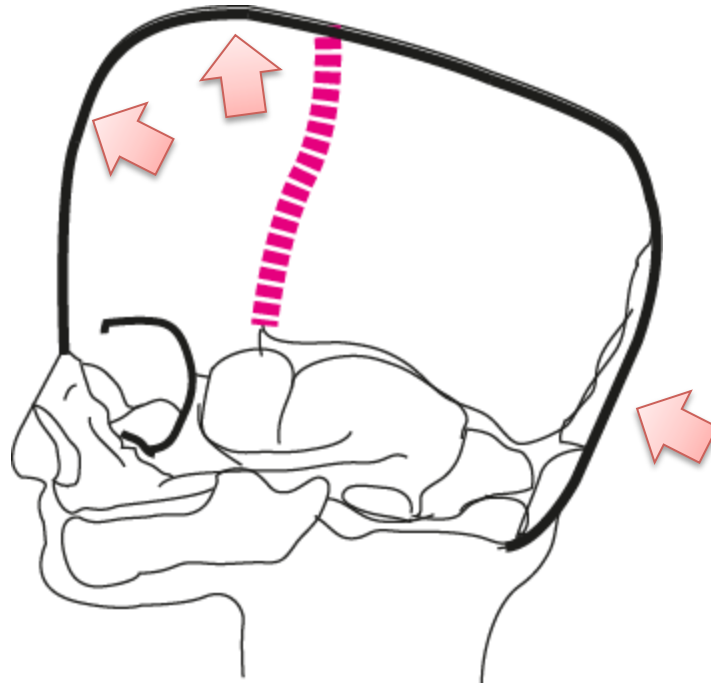
Trigonocephaly



Trigonocephaly

Brachycephaly

- Greek word *brachys*, meaning short.
- Both coronal sutures
- 10-20%



Bilateral coronal synostosis results in a prominent frontal bone, flattened occiput, and anterior displacement of the skull vertex.

Kabbani et al. Am Fam Physician. 2004 Jun 15;69(12):2863-2870.

Oxycephaly

- *Oxys, meaning sharp, and is a high, conical head with sharp bossing in the region of the anterior fontanelle*
- Coronal and sagittal sutures
results in an abnormally high conical head shape
- Encountered in syndromic types.

Cloverleaf skull deformity (Triphyllocephaly)

- (Derived from the Greek word *triphyllos*, meaning *trefoil, with 3 leaves*),

Multiple suture synostosis

Head shaped like a cloverleaf

Three bulges-two temporal and top

Pronounced constrictions in both Sylvian fissures

Frequency

Sagittal → 45⁰-50⁰

Unilateral coronal → 15⁰

Metopic synostosis → 5⁰

Lambdoid → 1.3%

CRANIOSYNOSTOSIS SYNDROMES

- 10-20 % of cases
- Autosomal Dominant
 - Linked to Chromosome 10
 - Multi-sutural, complex case
- If a suture is fused, check hands, feet, big toe and thumb

Crouzon's

- Autosomal - dominant pattern.
 - One of every 25,000 live births
 - 5 percent of cases of craniosynostosis.
-
- *Corde Mason A, Bentz ML, Losken W. Craniofacial syndromes. In: Zitelli BJ, Davis HW, eds. Atlas of pediatric physical diagnosis. 4th ed. St. Louis: Mosby, 2002:803-17.*

Clinical findings

- Brachycephaly,
- Significant hypertelorism, proptosis, maxillary hypoplasia, beaked nose

Intracranial anomalies

- Hydrocephalus, Chiari 1 malformation, and hindbrain herniation (70 percent).

- Normal intellect
- Normal extremities
- 5 % have Acanthosis nigricans
- 30 % have progressive hydrocephalus

Apert's - "Crouzon's with Hand Involvement"

- 1 in 55,000
- Varying intellect (50 % with MR)
- Syndactyly
- Cervical vertebral anomalies
- Rare hydrocephalus

PFEIFFER SYNDROME

- 1 in 2 lakhs
- Clover leaf skull in 20%
- Broad thumbs, broad great toes
- Intelligence is reported to be normal

CARPENTER SYNDROME

- Autosomal recessive.
- Syndactyly of feet
- Sagittal and lambdoid suture closes first coronal last
- Cardiac abnormalities

Diagnosis

- Clinical history
- Physical examination
- Radiographic studies

- Passage of the head through the birth canal deforms the head. This shape is retained for 2-3 weeks postnatally.
- **Early diagnosis is important**
The brain grows rapidly during this period
Delay only worsens the deformity of the head shape.

Detailed history

- Birth, sleeping position.
- Head tilt, torticollis
deformational plagiocephaly
- Family history
Abnormal head shape or multiple systemic problems (eg, cardiac, genitourinary, musculoskeletal)

Clinical Exam

- Head shape (from above, side)
- Ear and facial symmetry
- Palpate suture lines & fontanelles
- Look for ridging
- Look for associated anomalies
- If a suture is fused,
 check hands, feet, big toe and thumb

FUNCTIONAL CONSEQUENCES

Intra cranial hypertension

- Complicates one third of cases
- Principal indication of surgery
- ICP monitoring
- Syndromic forms → 30%
- 17% single suture
- **Causes** Abnormal venous drainage
Respiratory obstruction
Chiari malformations

Hydrocephalous

- 4% to 18%
- Communicating
- ?causes
- Cerebral maldevelopment
- Brain atrophy
- Abnormal csf circulation
- Venous outflow obstruction
- Hind brain herniation
- Aqueductal stenosis

Respiratory Abnormalities

- Syndromic craniosynostosis
- Manifest during sleep
- Maxillary hypoplasia, choanal stenosis, tonsillar hypertrophy
- Nasal stents, tonsillectomy or tracheostomy
- Nocturnal CPAP
- Surgical correction of midfacial hypoplasia

Feeding

- Abnormalities of palatal shape and movement
- Disordered dentition
- Dental malocclusion
- Nasogastric tube or gastrostomy

Vision

- Chronically raised ICP-----papilloedema----optic atrophy (Crouzon syndrome)
- Shallow orbits -----exposure
- Primary optic atrophy: compression, traction
- Early craniectomy

Plain Films

- Simple and inexpensive,
- Absent or line of increased density
- Harlequin appearance → coronal
- Cannot differentiate

Lambdoid synostosis and deformational plagiocephaly (plagiocephaly without synostosis).

- To visualize all the sutures, special Waters views must be taken.

Ultrasound

- Noninvasive

More effective than plain skull radiographs in detecting fused sutures

- Accuracy depends on a reliable and experienced operator.

CT Scan

- Standard for the complete visualization of the skull and cranial sutures.
- Detailed anatomy of the calvaria and the brain parenchyma
- Document effect of corrective surgery

MRI

- Complex craniosynostosis
- Improved definition of intracranial soft tissue structures
- Hindbrain herniation
- Identify sites of respiratory obstruction

Radio isotope scanning

- Diminished uptake → complete fusion

ICP monitoring

- Clinically occult – Majority
- Radiological signs inconclusive
- Deciding nature and timing of surgery
- Features of \uparrow ICT

Mean pressure > 15 mm Hg

Raised base line value

Prolonged plateau wave

Management

- Surgery vs. Conservative Management

Goal

- Normalization of deviated appearance, growth and function of skull
- Keep the suture open till brain growth is complete
- Rarely achieved

Indications

- Correction of cosmetic abnormality
- Early treatment of intracranial hypertension
- Optimizing brain growth
- Severe proptosis and impending corneal damage

Timing of surgery

Early operation(3-6 months)

- Rapid brain growth reshape bone
- Better compliance of brain dura and scalp
- Calvarium in an infant aged 3-9 months is much more malleable, easier to shape and providing a better outcome.

journal of pediatric neurosciences

- **REVIEW ARTICLE** Year : 2009 | Volume : 4 | Issue : 2 | Page : 86-99 *Pediatric craniofacial surgery for craniosynostosis: YN Anantheswar¹, NK Venkataramana²*
¹ Department of Plastic Surgery, Manipal Hospital, Kengeri, Bangalore, India
² Advanced Neuroscience Institute, BGS Global Hospital, Kengeri, Bangalore, India

- Prefers operating within **3-6 months** time frame to take advantage of the ability of the rapidly expanding brain and skull to grow more normally and so that the skull can be remodeled more readily.
- *Management Considerations in the Treatment of Craniosynostosis John A. Persing, M.D. New Haven, Conn. Plastic and Reconstructive Surgery • April 2008*
- Surgical intervention should be performed during infancy, preferably in the **first 6 months** of postnatal life, to prevent the further progression of the deformity and possible complications associated with increased intracranial pressure.

Plast Reconstr Surg. 2003 May;111(6):2032-48; quiz 2049. Management of craniosynostosis. Panchal J, Uttchin V. Oklahoma University Health Science Center, Oklahoma

- Early frontocranial remodelling is performed between 2 and 4 months for brachycephalies
- Other operated on between 6 and 12 months of age.
- For syndromal craniofacial synostosis, two-step operation: forehead advancement first
- Facial advancement later, to avoid the risk of frontal osteitis

- *Br J Plast Surg. 1994 Jun;47(4):211-22.*
- *Timing of treatment for craniosynostosis and facio-craniosynostosis: a 20-year experience, Marchac D, Renier D, Broumand S. Craniofacial Unit, Hôpital Necker-Enfants Malades, Paris, France*

Late intervention

- Closer the cranium is to the adult size, the less overcorrection for reconstruction and the better the ultimate skull shape.
- Higher risk of recurrent deformity
- Surgical correction more complex

Basic mechanisms

- Passive reshapement
 - Generous removal of bone
- Strip craniectomy
- Morcellation

- Active reshapement
 - Fronto orbital advancement
 - Cranial vault reshapement

Incision

- Zigzag bicoronal incision
- Prevents parting of the hair along a straight line
- Scar tends to spread less - redistribution of the forces.
- Incision begins slightly anterior and superior to the helix of the ear.
- Electrocautery is used cautiously

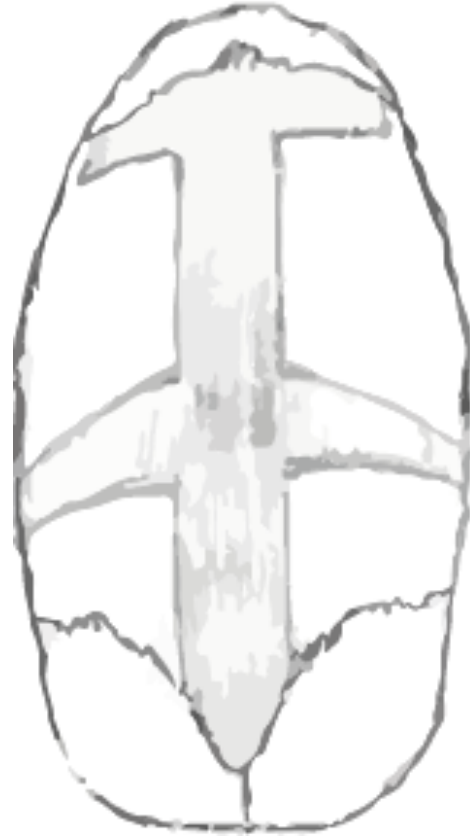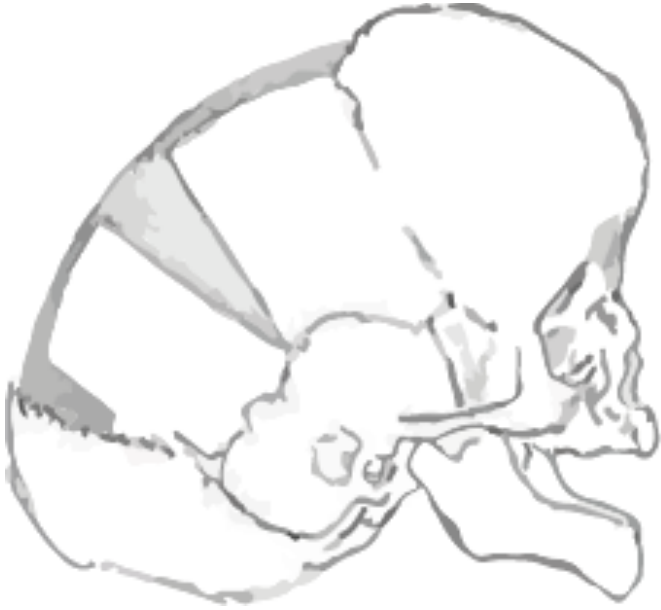
Sagittal craniosynostosis

- Objectives
 - Correction of scaphocephaly
 - Frontal bossing and occipital protrusion
- Initial surgical procedures included a narrow-strip craniectomy → higher restenosis .
- Wider and more extensive craniectomy
 - Do not address the frontal bossing and occipital bathrocephaly relied on the growing brain to correct these deformities.

- More extensive cranial vault remodeling with barrel-stave osteotomy
- Spring assisted cranioplasty
- With the advent of endoscopes in neurosurgery, extended-strip craniectomy is performed and the patient is placed in a custom-made molding helmet to correct the frontal bossing and bathrocephaly.
- Rapid recovery of the child and diminished need for blood transfusion,

-

Posterior



-

Anterior

Bilateral coronal stenosis

- Extended bicoronal craniectomies with reconstruction of the forehead.
- The supraorbital bar or brow is reshaped and advanced forward with the forehead.
- The reconstructed forehead and brow are rigidly fixed to the nose and lateral orbits with microplates.

Metopic stenosis

- Objectives increase in width of the bifrontal diameter, an increase in volume of the anterior cranial fossa, and normalization of frontal bone shape.
- The frontal bones and the frontoorbital bones are excised and transferred to the side assembly
The frontoorbital bar is advanced to create an appropriate brow position.
The interdacryon distance is increased by placing a bone graft between the 2 halves of the frontoorbital bars.

Syndromic craniosynostosis

Current surgical treatment approach

- Initial fronto-orbital and cranial vault remodeling,
- A midface advancement procedure with or without distraction (Le Fort III or monobloc)
- Secondary orthognathic surgery
To correct any dentofacial deformities (Le Fort I, mandibular osteotomies)

Conservative Therapy for Deformational Plagiocephaly

- Re-positioning
- If no improvement
by 6 months....
 - Helmet Molding

Long Term Follow-Up

- Speech
- Genetic Counseling
- Feeding / Swallowing
- Ophtho



Thank you