

# NEUROENDOSCOPY

VAMSI KRISHNA YERRAMNENI

The slide features a decorative background on the left side consisting of several vertical lines in shades of blue and orange. A large orange circle is positioned on the left, partially overlapping the text 'VAMSI'. Below it are several smaller orange circles of varying sizes, creating a cluster-like effect. The text 'NEUROENDOSCOPY' is centered in a dark blue, serif font, and 'VAMSI KRISHNA YERRAMNENI' is centered below it in a smaller, dark blue, serif font.

## INTRODUCTION

- The field of neuroendoscopy began with great promise.
- This new modality hold the potential to allow neurosurgeons to visualize anatomical structures never before studied in live patients.
- The perspective would be unique, a magnified view of the ventricular system viewed from within its walls.



# HISTORY

- **Max Nitze credited with designing first to device an endoscope this was a crude device composed of a series of lenses with an illumination source at the tip.**
- **First neurosurgical endoscopic procedure was performed by L'Espinasse. In 1910,**
- **he used cystoscope to perform fulguration of the choroid plexus in two infants with hydrocephalus.**

**In 1922, Walter Dandy described the use of an endoscope to perform choroid plexectomy. Dandy reported the first ventriculostomy for the treatment of hydrocephalus fenestration of the lamina terminalis via a craniotomy and a transfrontal approach.**

- **In 1923, Fay and Grant were able to visualize and photograph successfully the interior of the ventricles of a child with hydrocephalus by using a cystoscope.**
- **That same year, Mixer performed the first successful ETV by using a urethroscope in a 9-month-old girl with obstructive hydrocephalus.**



## HIST CONT.....

- In 1932, Dandy again reported use of an endoscope for choroid plexectomy.
- In 1934, Putnam described cauterization of the choroid plexus with an endoscopic device.
- The procedure was performed 12 times in seven patients, was successful in at least three cases, and resulted in two deaths.
- 9 years later Putnam reported his series of endoscopic choroid plexectomy in 42 patients. There were 10 perioperative deaths .15 patients failed to respond, although 17 had successful relief of increased intracranial pressure.



## CONT

- Scarff described his initial results after using a novel endoscope equipped with a mobile cauterizing electrode, an irrigation system that prevented collapse of the ventricles, and a movable operating tip that could be used to perforate the floor of the third ventricle.
- He punctured the floor of the third ventricle in one patient and achieved dramatic results: a 3-cm decrease in head circumference 6 weeks postoperatively.



## HISTORY

- In 1947, McNickle - percutaneous method of performing third ventriculostomy in patients with both obstructive and communicating hydrocephalus.
- Initially he used a 19-gauge needle and an endoscope for visualization.
- Despite the numerous reports that demonstrated the potential utility of neuroendoscopy, the field never gained favor in general neurosurgical practice.
- The fact was that poor magnification and illumination made neuroendoscopy difficult and unreliable.



# TECHNOLOGICAL BREAKTHROUGHS

- *New Lens Type.* In 1966, Hopkins and Storz developed a rigid endoscope that used a new type of lens, the SELFOC lens. Conventional lenses have a uniform refractive index,

The SELFOC lens used gradient index glass that had a refractive index that varied with the radial dimension of the lens.

Conventional endoscopes required the careful placement of a series of relay and field lenses to construct an appropriate image.

This new technology essentially obviated the need for the relay lenses while preserving light transmission. These lenses also created a wider effective field of vision.



## *INVENTION OF CCD S.*

- In 1969, George Smith and Willard Boyle invented the first CCDs at Bell Laboratories.
- The CCDs usually a silicon chip, which are capable of converting optical data into electrical current. “Charge-coupling” refers to the manner in which the electronic charges are stored and transmitted.
- The CCDs are ideal for use in low-light environments and were readily incorporated into the system’s apparatus, resulting in both improved quality of the transmitted images and decreased size of the endoscopic systems.



# FIBREOPTICS

- 
- . first used in the 1950s and 1960s, and refined further in the 1970s.
- allowed the light source to be separated from the rest of the endoscope.
- In 1963 Scarff described the first use of a “fiber lighting” system with an external light source for ventriculoscopy.
- These advances, which brought together brighter light sources and cameras with improved resolution, the two key components of any endoscope, were an important part of the rediscovery of neuroendoscopy.



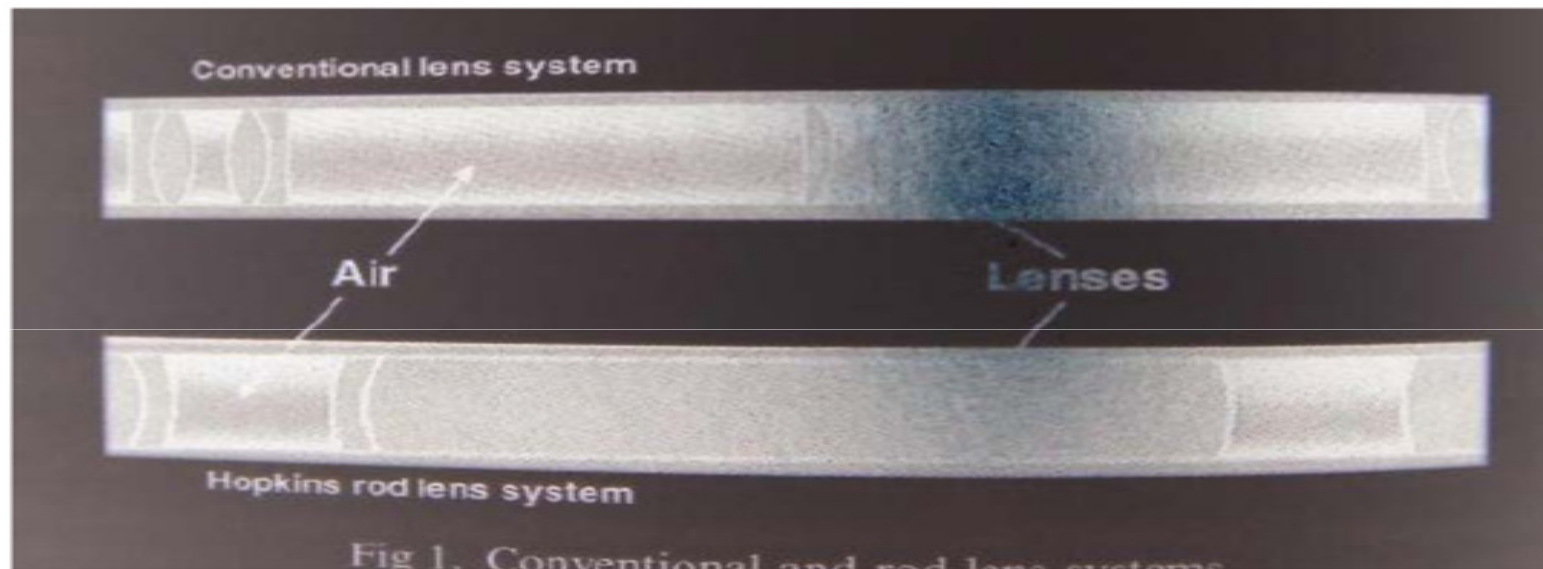
# *REDISCOVERY OF NEUROENDOSCOPY*

- In 1978, Vries described his experience treating five patients with hydrocephalus, in whom he performed ETVs by using a fiberoptic endoscope..

In 1990 Jones and colleagues described a 50% shunt-free success rate for ETV in 24 patients with various forms of hydrocephalus.

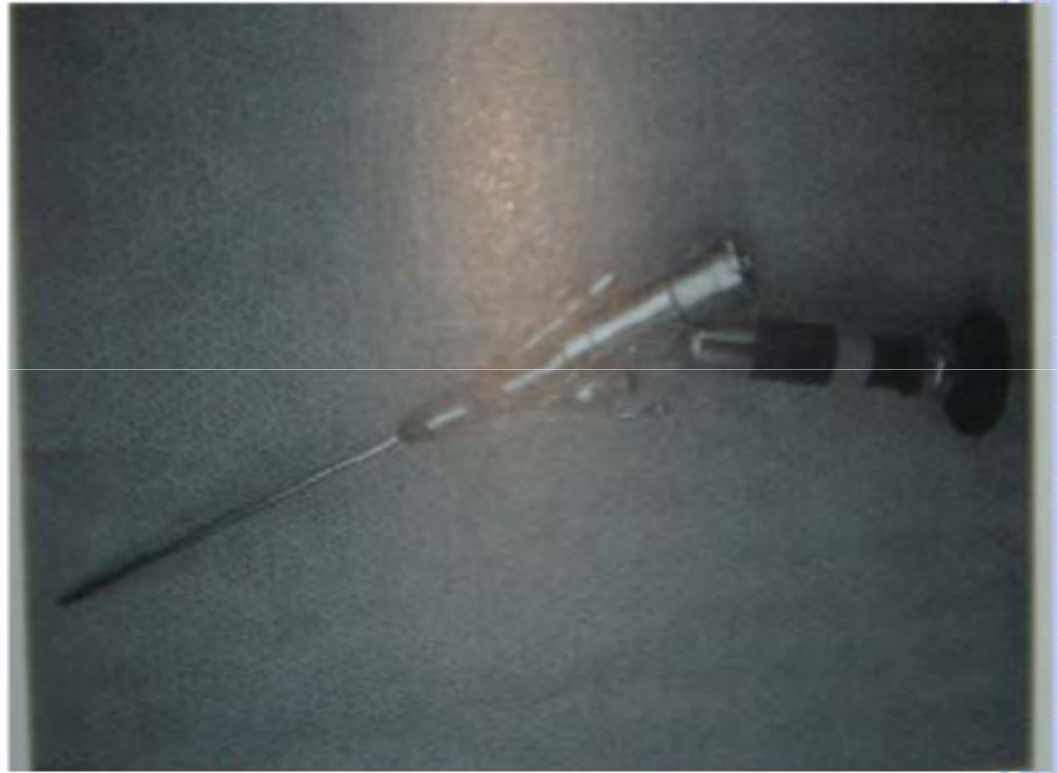
- Four years later, Jones and coworkers had improved their success rate to 61% in a series of 103 patients.
- Currently ETV is primarily used to treat obstructive hydrocephalus.


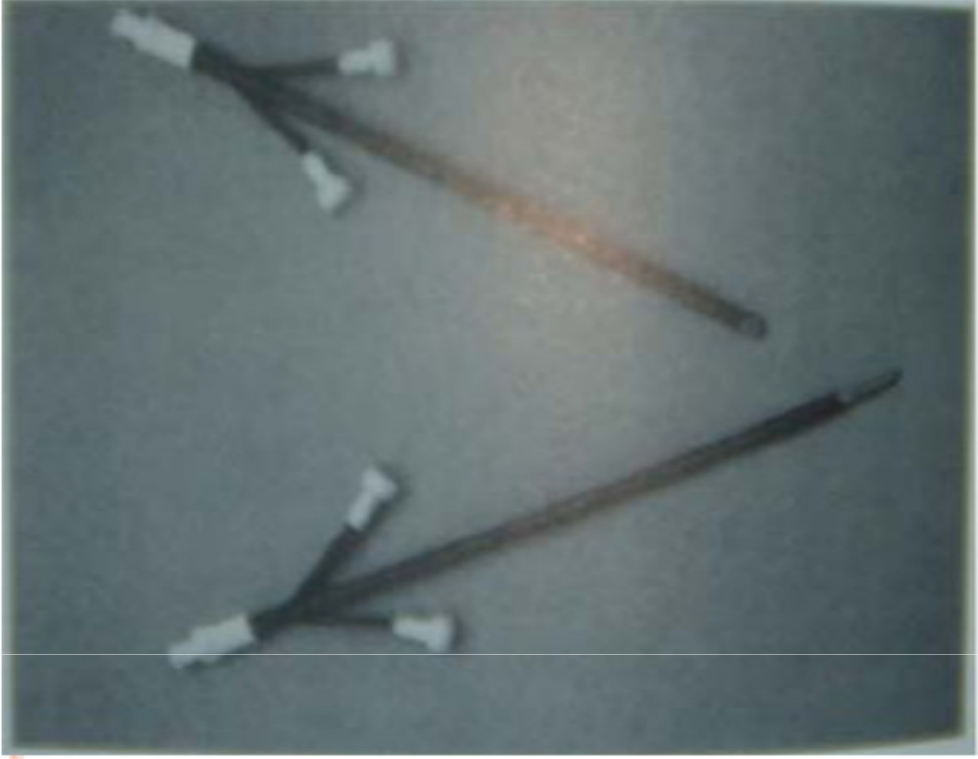
# INSTRUMENT DESIGN

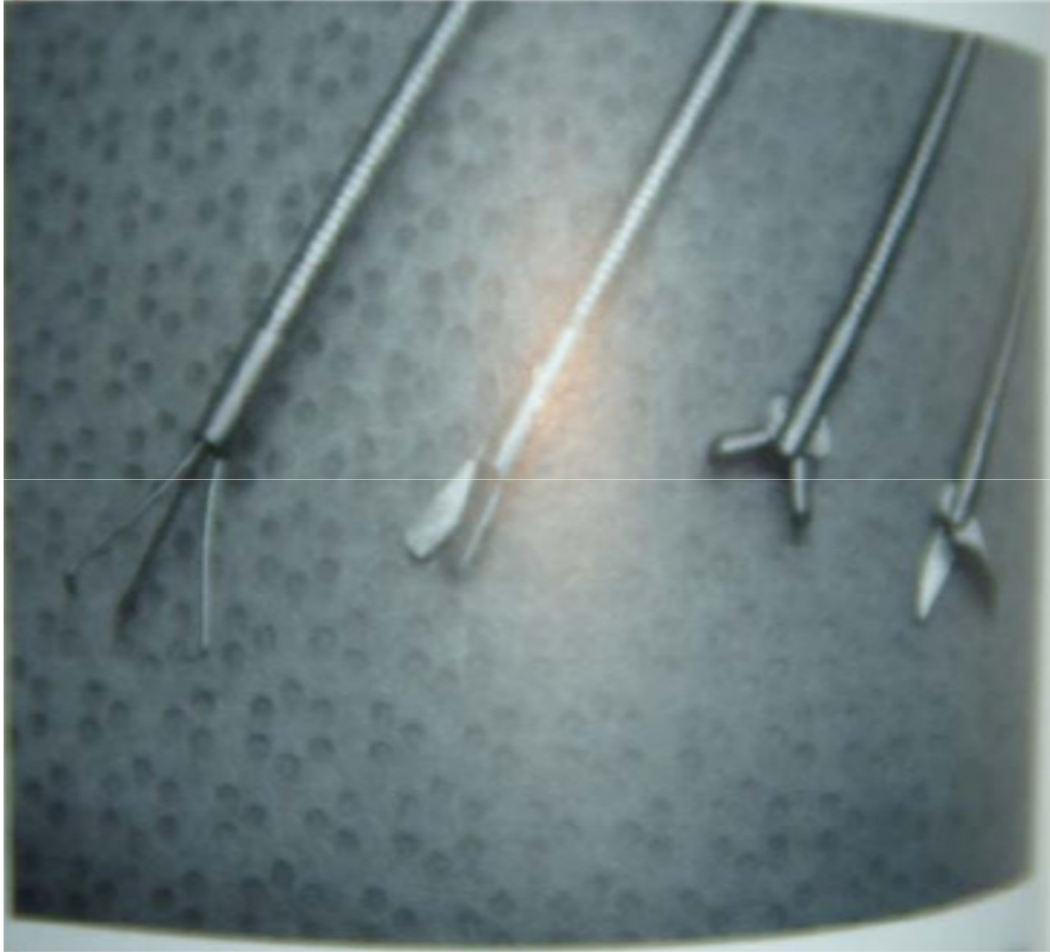


## 3 CHIP CCD CAMERA









## Comparison of rigid and flexible scopes

	<u>Rigid scopes</u>	<u>Flexible scope</u>
<b>Advantages</b>	Better image higher resolution Wider view, Better colour Better light transmission Light weight of disposable scopes	Steerability Application in spine
<b>Disadvantages</b>	Less maneuverable Not applicable in Spine.	Poor image Pixel granules Narrower view Less true colour Worse light Smaller working channel Limited selection of scopes and instruments



# AREAS OF NEUROENDOSCOPY

- The endoscope is currently being used for all types of neurosurgically treatable disorders:
- intraventricular tumors,
- skull base tumors,
- craniosynostosis,
- degenerative spine disease,
- intracranial cysts,
- rare subtypes of hydrocephalus.



# INDICATIONS OF ETV

- Non-communicating hydrocephalus
- Congenital lesions
  - stenosis of aqueduct of Sylvius
  - obstruction of foramen of Monro
  - atresia of foramina of Luschka & Magendie
  - Dandy-Walker cyst



# WELL ACCEPTED INDICATIONS

- Aqueductal stenosis
- Arachnoid cyst & ass. hydrocephalus
- Neoplastic etiology e.g. tectal plate tumors
- Intraventricular neurocysticercosis
- Dandy Walker syndrome and its variants



# RELATIVE INDICATIONS

- Patients with repeated shunt infections
- Post-meningitic hydrocephalus
- Hydrocephalus following intraventricular hemorrhage



# THIRD VENTRICULOSTOMY PROCEDURE

- A trepanation was performed in the Kocher point. When a neuroendoscope is introduced to a lateral cerebral ventricle,
- it is necessary to identify the foramen of Monro, which is surrounded by the choroid plexus and septal and thalamostriate veins.
  
- The correct point for the third ventriculostomy is the so-called hypophysiomamillary triangle
- (an area between the infundibular recess and mamillary bodies) away from the bifurcation of the basilar artery and the portal circulation of the hypophysis.



## ETV

- There are different techniques to perforate the bottom of the third ventricle. The perforation can be made with the use of sharp instruments such as a very thin neuroendoscope itself or coagulation.
- Both methods are connected with increased risk of injury to the basilar artery.
- The third ventriculostomy can be made with the use of Fogarty's catheters. The crucial point is to perforate Liliequist's membrane.
- Hemostasis done with bipolar cautery probes.



# ETV FAILURE

- **Follow-up for 5-6 years**
  - Maximum incidence of failure: first 1-2 months
  - No failure reported after 5 yrs.
- **Early : within 4 wks**
  - Non-absorption from arachnoid granulation despite good MRI flow
- **Delayed : after 4 wks**
  - Stoma closure gliosis / scarring (6-15%)
  - No MRI flow

Jones et al Min. Inv. Tech NS 1993  
Siamin et al Childs Nervous System 2001  
Cindali et al Min. JNS 1999



## ETV FAILURE

### o Failure rate 10-40%

- Primary technical failure: difficult perforation, <sup>2<sup>nd</sup> membrane</sup> imperforation
- Secondary technical failure: Stoma closure gliosis / scarring
- CSF absorption failure

### o Major complication <2%

- CSF leak
- Meningitis <1%
- Damage to hypothalamus: DI, SIADH
- Injury to vessels e.g. basilar artery injury



CONT.

### Etiology (Most imp. Factor)

- Previous meningitis
- Ass. myelomeningocele
- Shunt infection
- Repeated shunt malfunction
- Chiari malformation
- Technical: imperforated 2<sup>nd</sup> membrane



# NEUROENDOSCOPY VS SHUNT

**In infants suffering from chronic noncommunicating hydrocephalus after effective neuroendoscopic procedures, the rate of head circumference growth does not decrease, which is very different in comparison with infants treated by shunt implantation.**

- **The rate of head circumference growth in infants after neuroendoscopic procedures does not constantly increase as a function of time following the operative treatment, despite the fact that, in some children of the group, the head circumference could become higher according to the percentile chart.**
- **There are significant differences after an effective neuroendoscopic procedure between the rate of head growth in neonates, which is lower, and in infants, which is higher.**
- **In children suffering from chronic hydrocephalus, the observed decrease in ventricular size after neuroendoscopic procedures is smaller than after shunt implantation.**
- **In infants suffering from Chiari II malformation, after neuroendoscopic operative treatment, the average ventricular size is larger than in other children.**
- 

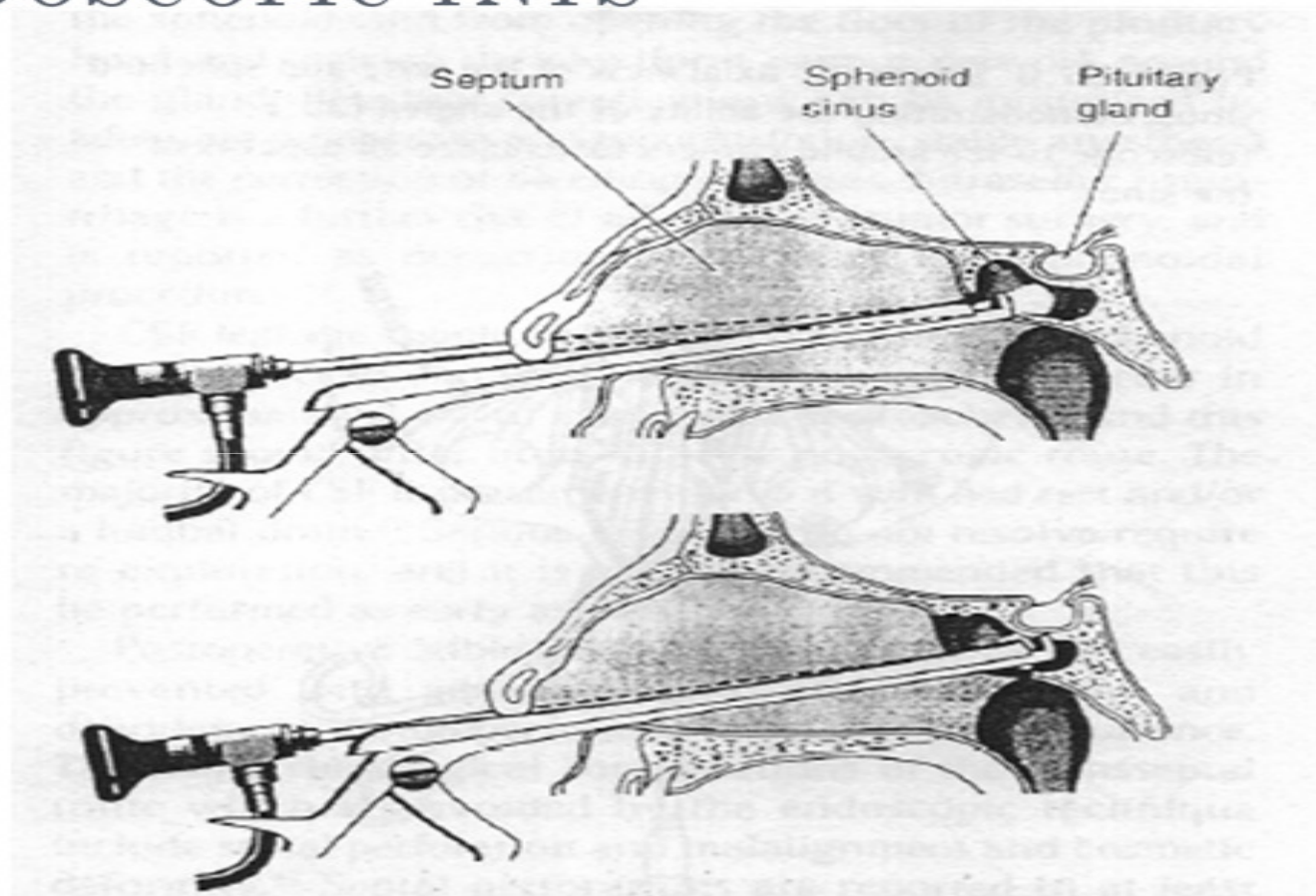


## FOURTH VENTRICLE NCC EXCISION

- A relative contraindication to resection of cisternal cysts is the presence of significant inflammation, demonstrated by extensive enhancement of the cisterns and cysts on MR images.
- In these cases, the arachnoid and cyst walls are often opaque and indistinguishable, making exploration and removal of the cysts difficult and hazardous.
- If surgical exploration is considered, a low threshold for converting from the excision to placement of a shunt must be maintained.



# ENDOSCOPIC TNTS



## ENDOSCOPIC SHUNT PLACEMENT

- Goal is to place the ventricular catheter tip away from the choroid plexus.
- Small diameter endoscope as stylet with in the ventricular catheter may allow more accurate catheter positioning with in the ventricles.
- May decrease the chances of completely missing the ventricles.
- But does nt improve the surgical outcome once the tip is with in the ventricles.



# ENDOSCOPIC REPAIR OF CSF RHINORRHEA:

- Anterior skull base defects are repaired.
- Intrathecal fluorescein administration helps in localising the defect.
- Endoscope passed through nostrils and fibrous tissue excised and graft placement done



# ENDOSCOPIC COLLOID CYST EXCISION

- Ventricular enlargement renders the endoscopic intervention easier;
- The lesions are approached via a transcortical, transventricular, and transforaminal route. In general, the entry point should be located opposite the dominant hemisphere.
- In case of asymmetric ventricular dilation, the approach is via the wider ventricle.
- However, an asymmetric foramen of Monro with asymmetric covering of the cyst by the fornices is more important.
- Of course, the route of access with the least potential for fornix damage should be chosen.
- For accurate planning of the ideal approach, neuronavigation is indispensable
- Usually, the burr hole is placed behind the hairline and as far laterally (approximately 5-6 cm paramedian) as possible to allow straight access without damage to the caudate nucleus and fornix .



## COLLOID CYST

- . Total cyst extirpation is attempted but not at the expense of severe hemorrhage.
- In these cases, the best option seems to be to coagulate the residual part of the cyst wall .
- However, the question remains whether small remnants of the capsule that may be left in place cause cyst recurrence.



# SPINAL ENDOSCOPY

- The evolution of minimally invasive spine surgery dates from the 1929 report by Dandy (, in which he described removal of loose cartilage from the intervertebral disc.
- In 1931, Burman introduced the concept of myeloscopy for direct spinal cord observation.
- In 1934, Mixter and Barr reported an open hemilaminectomy with intraoperative discotomy for treatment of intervertebral disc rupture into the spinal canal.
- \In 1938, Pool (expanded on Burman's work and reported myeloscopic inspection of the dorsal nerve roots of the cauda equina.
- In 1942, Pool introduced the concept of intrathecal endoscopy and reported the results of more than 400 myeloscopic procedures.



## CONT

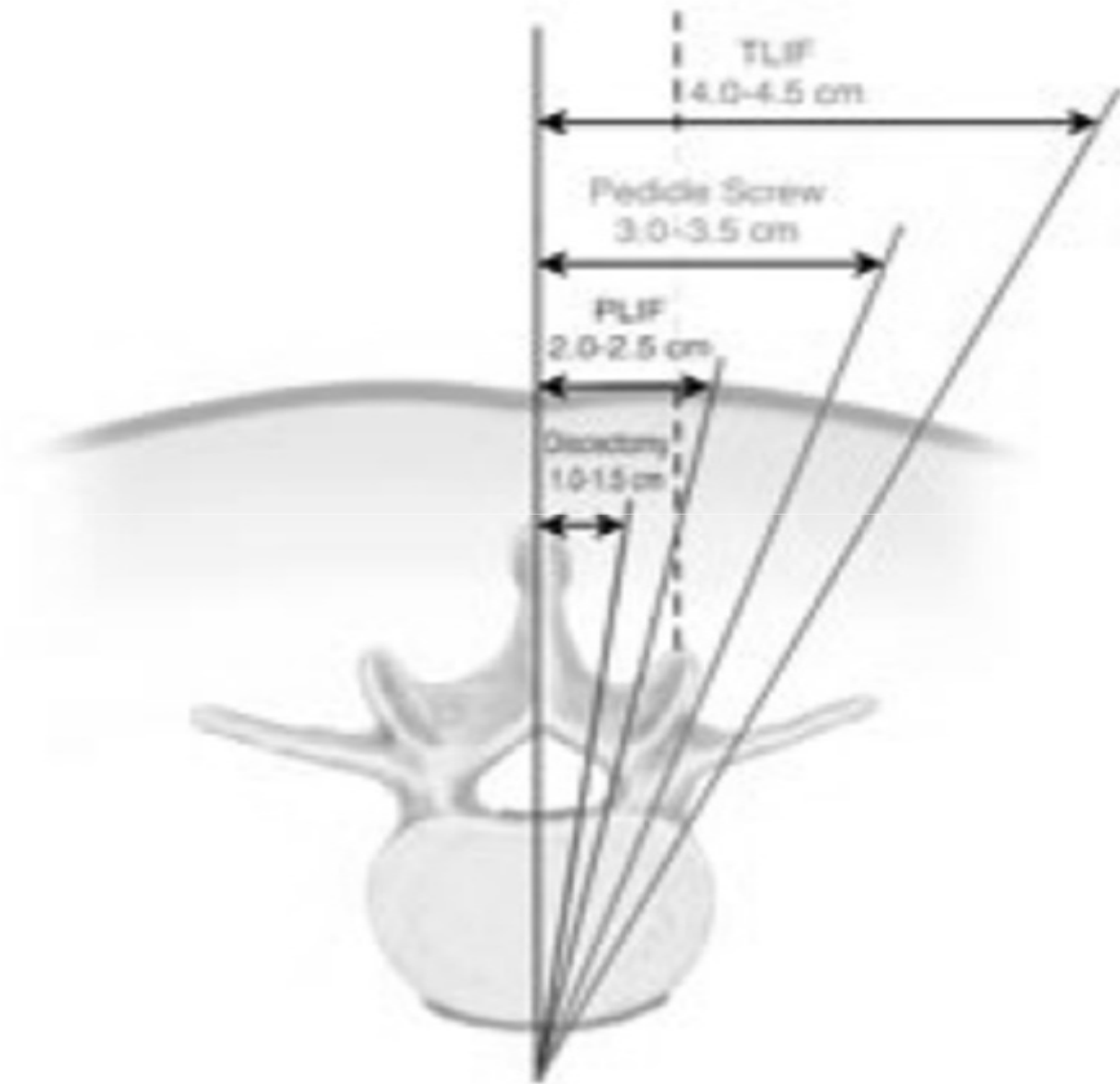
- Myeloscopy fell out of favor for a time because of the morbidity associated with insertion of a large-bore scope into the neural cavity. The state of spinal endoscopy remained essentially the same until Ooi et al used an endoscope to examine the intrathecal space before surgery.
- Color photographs were taken during the procedure and were later correlated with the findings noted during the open procedure.
- Using improved technology, Ooi et al. were able to describe pathological features in greater detail, including chronic arachnoiditis and nerve root excursion during claudication associated with lumbar spinal stenosis.
- In 1989, Stoll et al. described epiduroscopy with a fiberoptic scope as an adjunct to open surgical procedures. As part of a FDA-approved study, a multicenter evaluation of 60 patients, for observation of the epidural space, was performed. No complications were observed during the study.

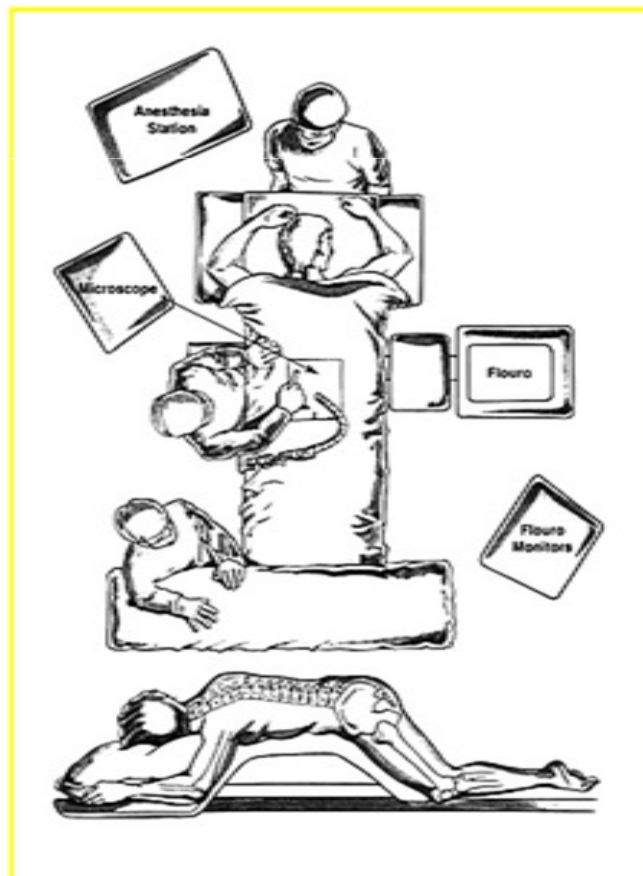


## KAMBIN S TRIANGLE

- Percutaneous lumbar disc surgery is performed through the triangular working zone, or Kambin's triangle-
- This triangular zone is defined by the exiting nerve root or spinal nerve.
- The nerve makes up the hypotenuse of the triangle and therefore defines the anterior and superior safe working margins. The nerve makes an angle of 40 degrees with the dura as it exits under the pedicle.
- The hypotenuse is an average of 23 mm long. The longer leg is defined inferiorly by the superior endplate of the distal vertebrae and measures 18.9 mm on average. The shorter leg of the triangle is defined by the superior articular facet of the distal vertebrae and usually measures 12.3 mm..







## Patient Positioning

Prone with abdomen free

(Wilson Frame or Andrews table)

Spine Flexed

Depending on surgeon preference,  
microscope can be placed  
on either side of patient.



# Guide Wire Placement

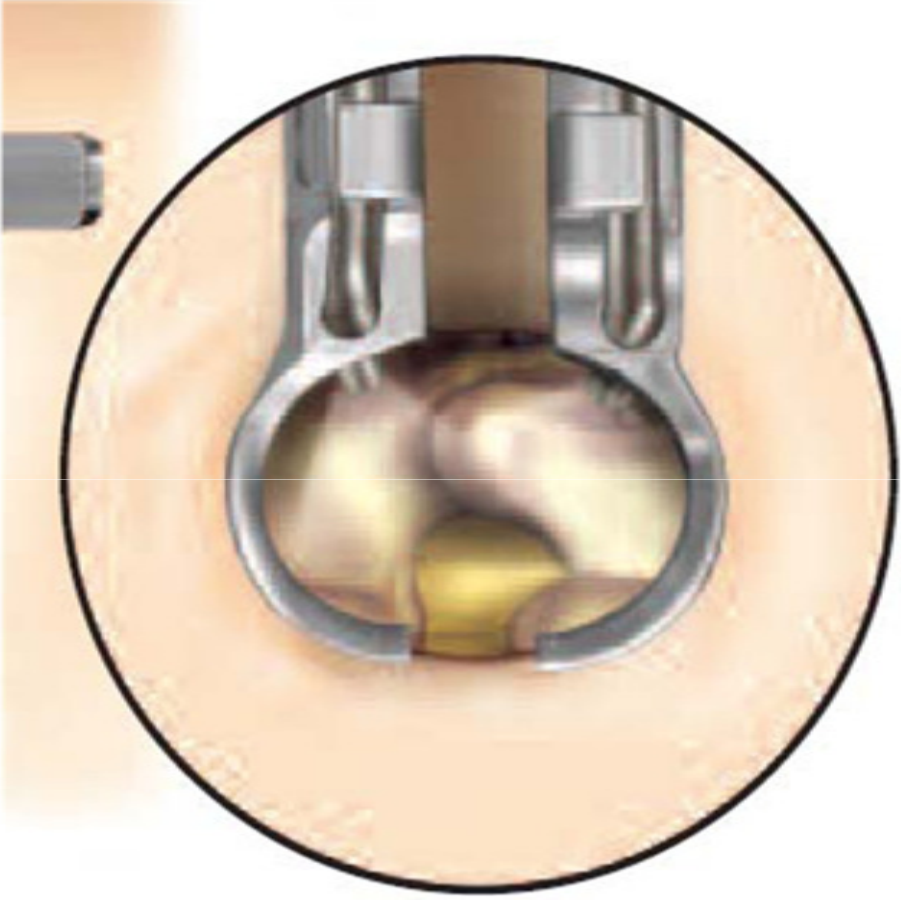
- Spinal needle is placed into paraspinous musculature 1.5cm off of midline at the appropriate level confirmed using lateral fluoroscopy
- The spinal needle is removed and a vertical incision is made at the puncture site
- The guide wire is placed through the incision and directed toward the inferior aspect of superior lamina under lateral fluoroscopy

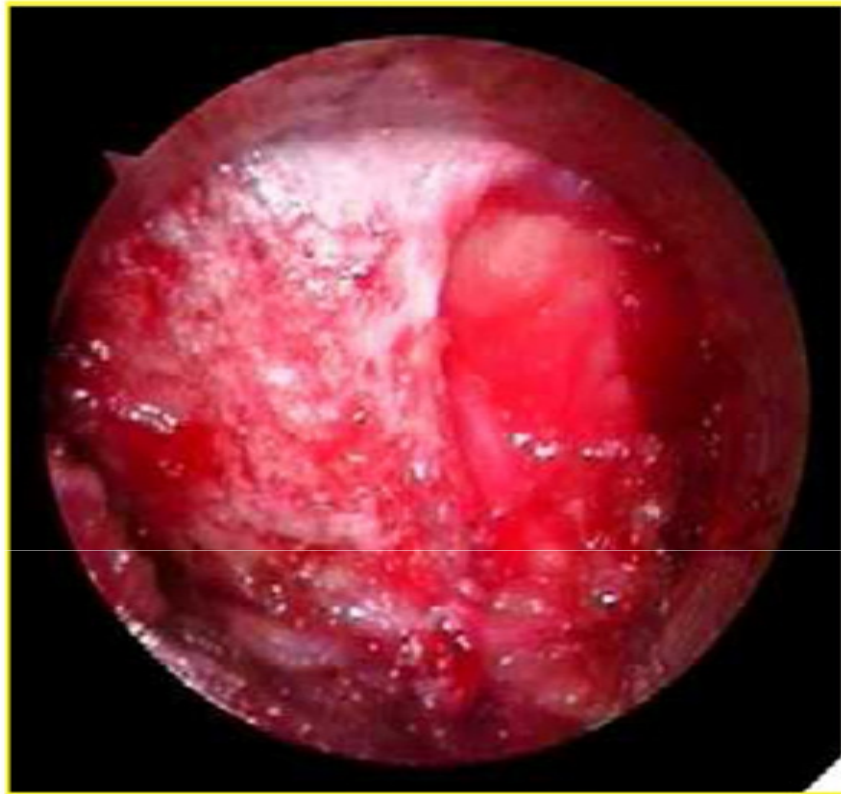

# Initial Dilator Insertion

- Insert initial cannulated soft tissue dilator over the guide wire
- Once the fascia is penetrated remove guide wire and advance the dilator down to the inferior edge of superior lamina
- Confirm placement of initial dilator using lateral lateral fluoroscopy
- Use the initial dilator to palpate the lamina in both the coronal and sagittal planes
  - The tip of the dilator is used to sweep the paraspinal musculature off the laminar edge
  - This maneuver affirms coronal placement and expedites soft tissue removal



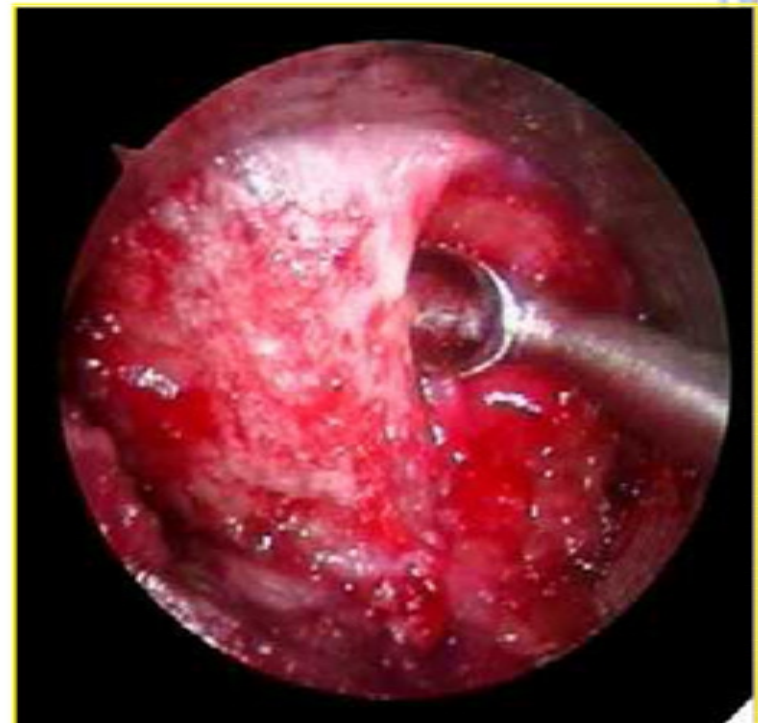

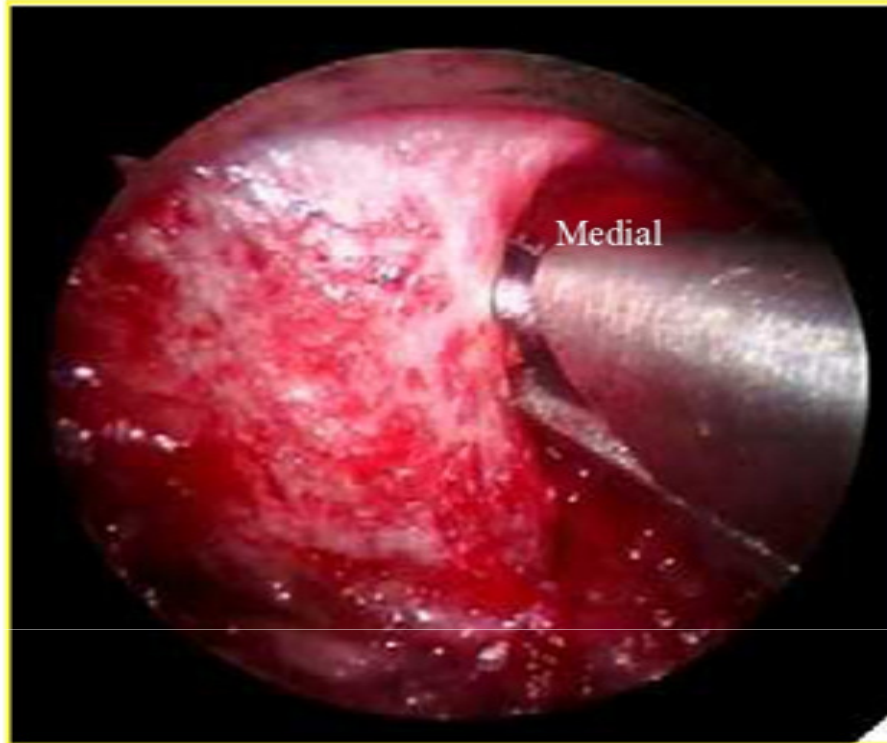


- The laminar edge is identified and the ligamentum flavum is detached from the undersurface of the lamina with a curved curette

## Soft Tissue Removal

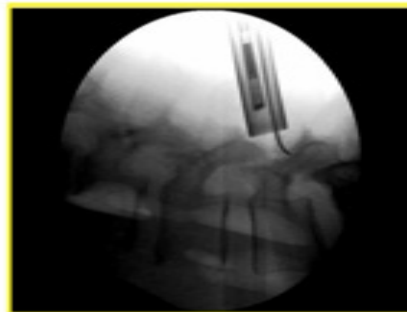
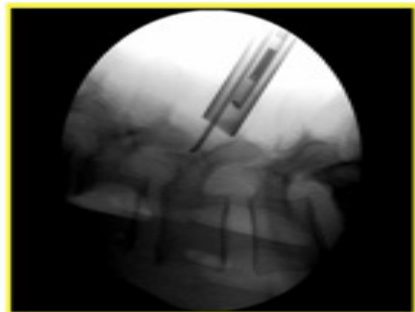
- Soft tissue over the lamina and interlaminar space is removed with a pituitary rongeur
- It is essential to remove all soft tissue exposed in the operative corridor in order to maximize the working space within the Tubular Retractor





## Laminotomy

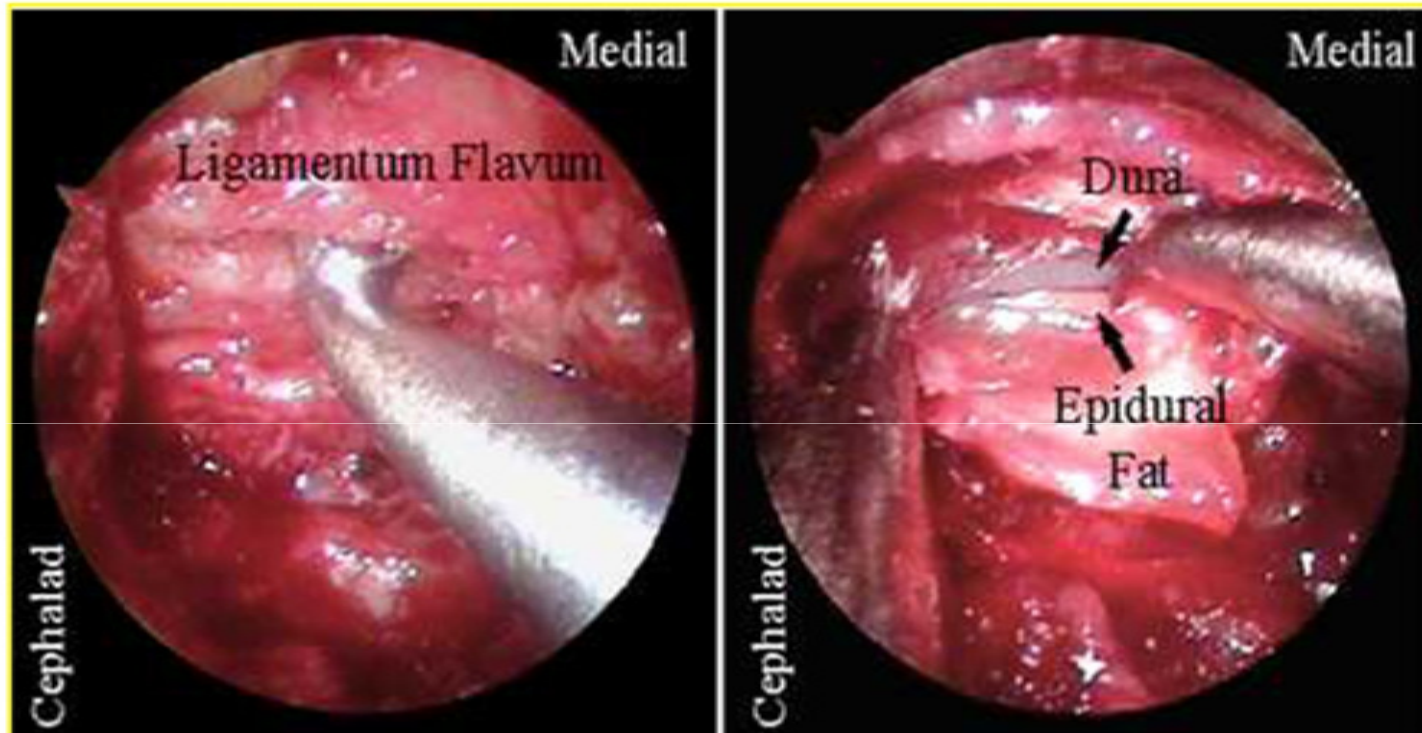
- A hemilaminotomy / medial facetotomy is performed with a Kerrison punch or high speed drill.
- Effective utilization of lateral fluoroscopy will help tailor the necessary dissection to access specific pathology



- \* If the pathology is beyond the confines of the Tubular Retractor, the retractor can be moved or angled over the pathology by a process known as wandling. Wandling allows the surgeon to place the objects of interest in the center of the operative corridor

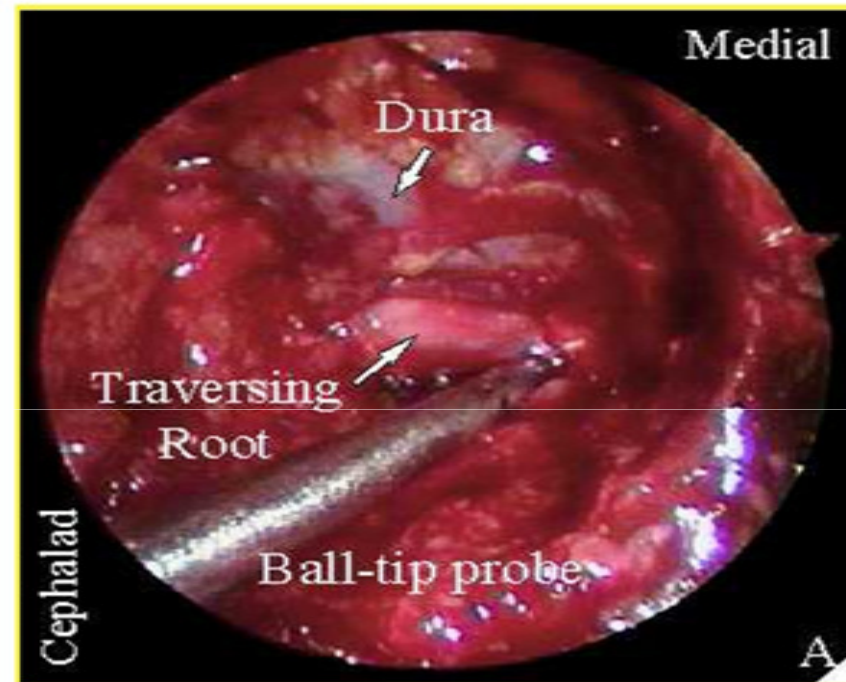
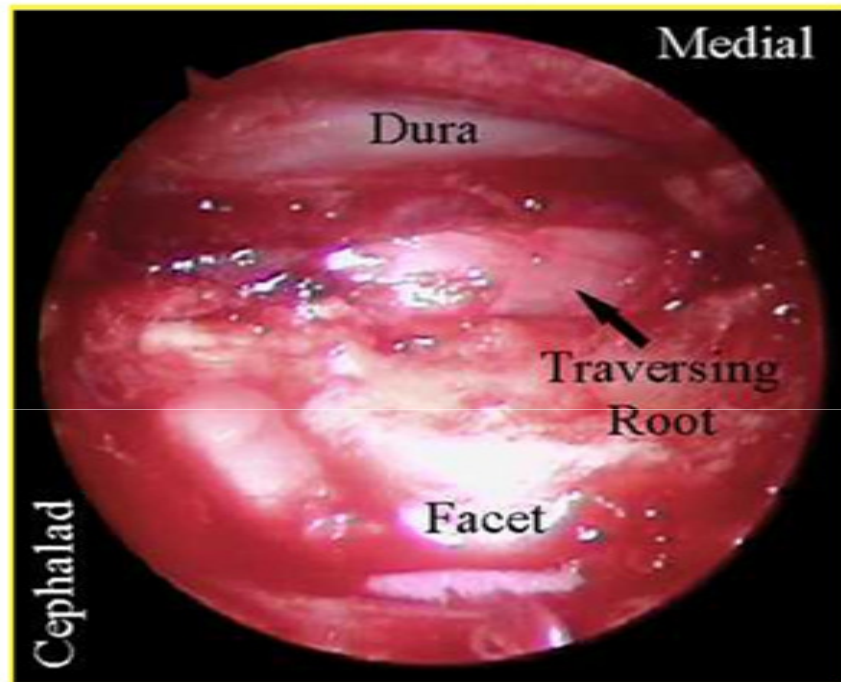


# Ligamentum Removal



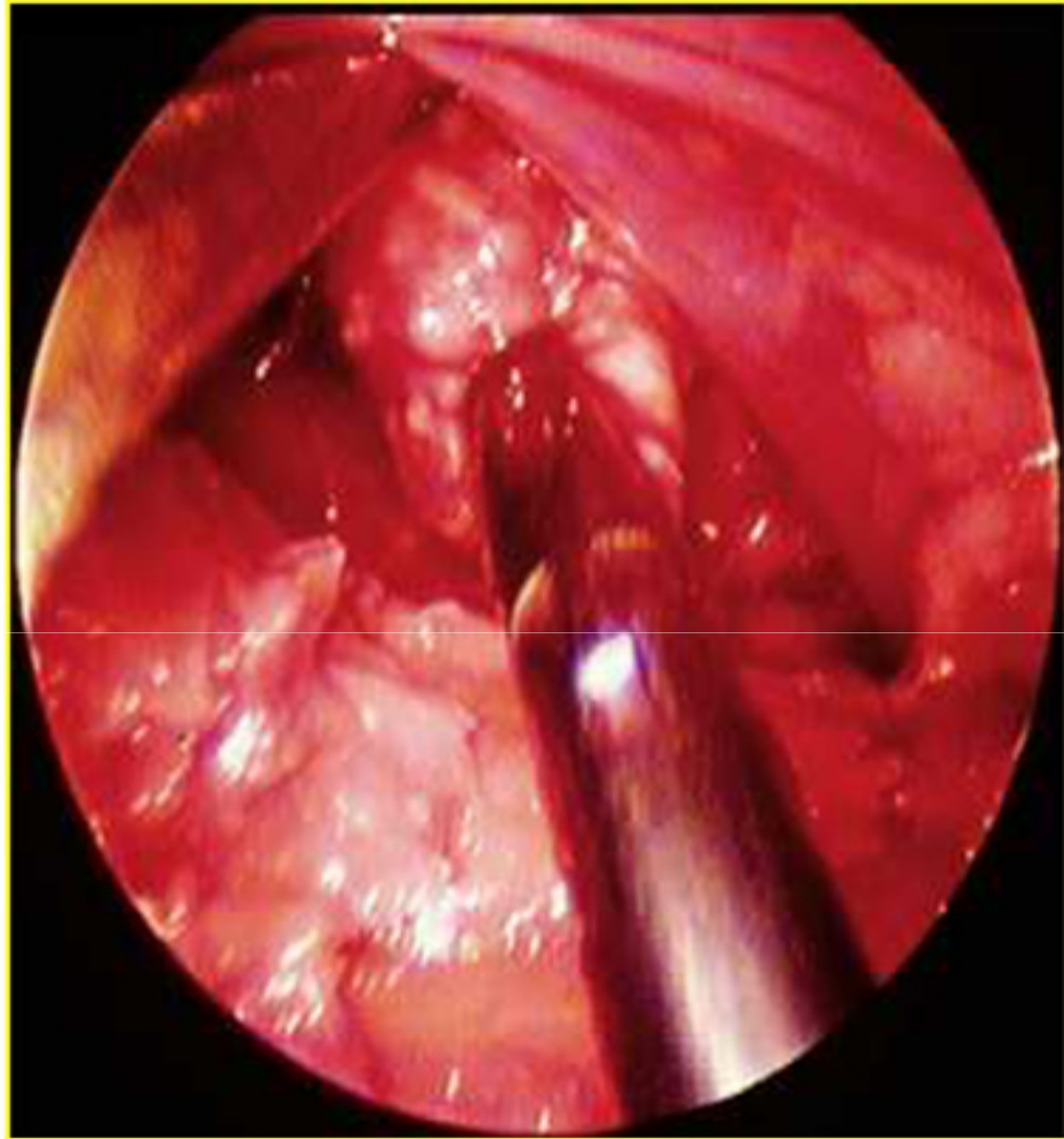
- The ligamentum flavum is opened with an angled curette. The curette is placed under the remaining superior lamina where the ligament is thin
- The ligament is penetrated with a curette utilizing a twisting motion.
- It is peeled back caudally and dorsally, then resected with a Kerrison punch

# Nerve Root Identification



- The dura and traversing nerve root are identified
- The nerve root is retracted medially utilizing a Penfield dissector, Love style or suction retractor
- The volar epidural space can be explored and epidural veins can be cauterized





## Discectomy

- An annulotomy can be performed with the Sheathed Annulotomy Knife while protecting the nerve root with the retractor



## MICROENDOSCOPIC DISCECTOMY

‘

- reduction of tissue trauma.
- Less duration of hosp. stay
- The ability to visualize the nerve root and disc disease directly, and
- allowing bony decompression (i.e., spinal and lateral recess stenosis).



# ENDOSCOPIC SPINAL SURGERY

- Endoscopic Posterior Cervical Laminoforaminotomy ; This muscle-splitting approach is effective in limiting postoperative pain and muscle spasms while maintaining the integrity of midline posterior muscular and ligamentous attachments to the spine
- Anterior Cervical Foraminotomy ; The anterior cervical foraminotomy procedure is effective for unilateral radicular symptoms and can be performed on an outpatient basis



## THORACOSCOPIC PROCEDURES

- Thoracoscopic Procedures ; The potential complications are similar to those associated with open thoracotomy, although the incidence varies.
- There is a reduced incidence of post-thoracotomy pain, intercostal neuralgia, pulmonary dysfunction, and scapular dysfunction associated with a thoracoscopic compared with an open thoracotomy approach .
- Complications may arise from many factors, including anesthesia, patient positioning, port placement and access, and manipulation of instruments, with injury to the lung parenchyma and thoracic vascular structures .



# THORACOSCOPIC DISSECTOMY

- The anatomic dissection of the spine was essentially identical to the steps for thoracic discectomy using open thoracotomy .
- A cavity was drilled in the dorsal vertebral body and disc space to provide enough space to insert tools, to avoid manipulation of the spinal cord, and to expose normal dura rostral and caudal to the herniated disc.
- The cavity was pyramidal or hemispherical for small- to moderate-sized disc herniations and rectangular for larger herniations. The spinal cord and nerve roots were decompressed microsurgically under direct visualization using endoscopic spine tools with calibrated shafts and fine-angled tips.



# THORACOSCOPIC SYMPATHECTOMY

- For palmar hyperhidrosis, the T2 ganglion and associated nerve of Kuntz were identified visually, isolated surgically, and divided with endoscopic cautery scissors. The associated nerve of Kuntz was found in fewer than 5% of patients.
- **Axillary hyperhidrosis** was present, the T3 and T4 ganglions were isolated. The sympathetic chain was transected in situ, creating a gap of 5 mm or more between the cut ends.
- The effectiveness of sympathectomy was gauged by monitoring palmar temperature for more than a 1°C increase in temperature after the sympathetic chain was transected



## THORACOSCOPIC SYMPATHECTOMY

- A number of complications can result from thoracic endoscopic sympathectomy; they include
- compensatory hyperhidrosis syndrome (CHS),
- Horner's syndrome,
- intercostal neuralgia,
- pneumothorax,
- gustatory sweating
- vascular injury . increased sweating in non-denervated areas,



## OTHER PROCEDURES

- Thoracoscopic-assisted Treatment of Thoracic and Lumbar Fractures
- Complications that can occur during anterior lumbar interbody fusion (ALIF)



# ENDOSCOPICALLY ASSISTED TRANSORAL-TRANSPHARYNGEAL APPROACH TO THE CRANIOVERTEBRAL JUNCTION

- By use of the 30-degree-angled endoscope, clivus can be visualised without the need for extensive palatal splitting.
- A broader field of view is obtained using the endoscope, and the lateral and inferior fields can be visualised well by rotating the endoscope.
- enable us to avoid performing extended maxillotomies in in patients requiring more aggressive procedures would have been necessary if microscopic technique were used.
- avoids splitting the soft palate. Minimizing the swallowing difficulty that sometimes results from this maneuver.

