

CNS Tuberculosis imaging and surgery

Moderators

Dr Ashish Suri

Dr Deepak Gupta

Presented By

Dr Ajay Bisht

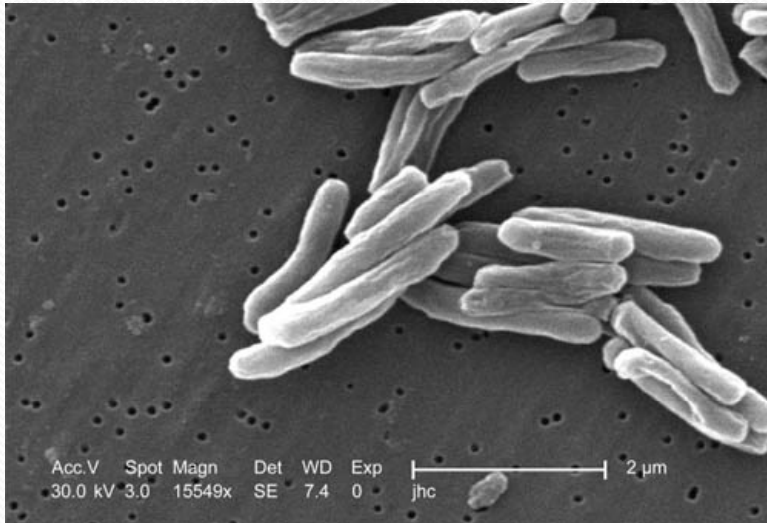
Tuberculosis

- ▶ As old as recorded history
- ▶ Symptoms described in the Rig Veda (1500 BC)
- ▶ Unequivocal lesions in Egyptian mummies
- ▶ Odier, Ford described meningeal TB 1790
- ▶ Surgical excision Wernicke and Hahn 1882,

Tuberculosis

- CNS tuberculosis complicates 10% of all TB
- Never the first manifestation
- Occurs within 6-12 months
- Circle of Willis more frequently involved than the basilar system

Mycobacterium tuberculosis



- Acid fast bacillus
- Does not stain on gram stain
- Obligate aerobes
- Difficult to grow
- High lipid in cell wall
- Hominis/ Bovine/ Avium

Pathogenesis

- May develop during initial infection/ reactivation
- Haematogenous dissemination
 - Commonest
 - Focus in brain (Rich focus)
 - Rupture of focus into subarachnoid/ ventricular space
- Contiguous spread

CNS tuberculosis

- Intracranial
 - Parenchymal
 - Meningeal
 - Osseous
- Spinal
 - Parenchymal
 - Meningeal
 - Arachnoiditis
 - Osseous

Epidemiology

- Incidence varies blacks > whites
- Predominantly in the young (50% <10)
- Abscess in 4-8% (20% with HIV)

Pathology

- Immature lesions – multiple tubercles in oedematous brain
- Mature: avascular mass, nodular extensions, yellowish gritty caseous areas
- 60% attached to dura

Pathology (parenchymal)

- Can be present anywhere
- Cerebellum in children
- Cerebral hemisphere and basal ganglia commoner in adults

Pathology (tuberculoma)

- Tuberculoma (classical lesion)
- Tuberculoma en plaque
- Tuberculous abscess
- Cystic tuberculoma
- Multiple grape like tuberculoma
- Microtuberculoma
- Calcified tuberculoma
- Tuberculous encephalopathy

Pathology (tuberculoma)

- Dastur described six main types
 - Parenchymal changes.
 - (1) Ventriculitis
 - (2) Border-zone encephalitis
 - (3) Infarction
 - (4) Internal hydrocephalus
 - (5) Diffuse oedema
 - (6) Tuberculoma

Pathology (meningeal)

- Classically Commonest in 6m – 3 years
- Now adults 50%
- Thick exudate encasing nerves, vessels
- HCP, tuberculoma, arachnoiditis
- Diffuse perivasculitis
- Infarcts
- Pachymeningitis

Diagnosis

- Montoux test
- Hb/ ESR
- CXR
- ELISA
- CSF
- PCR
- Imaging
- Biopsy

Imaging

- X ray
- Angiography
- CT
- MRI



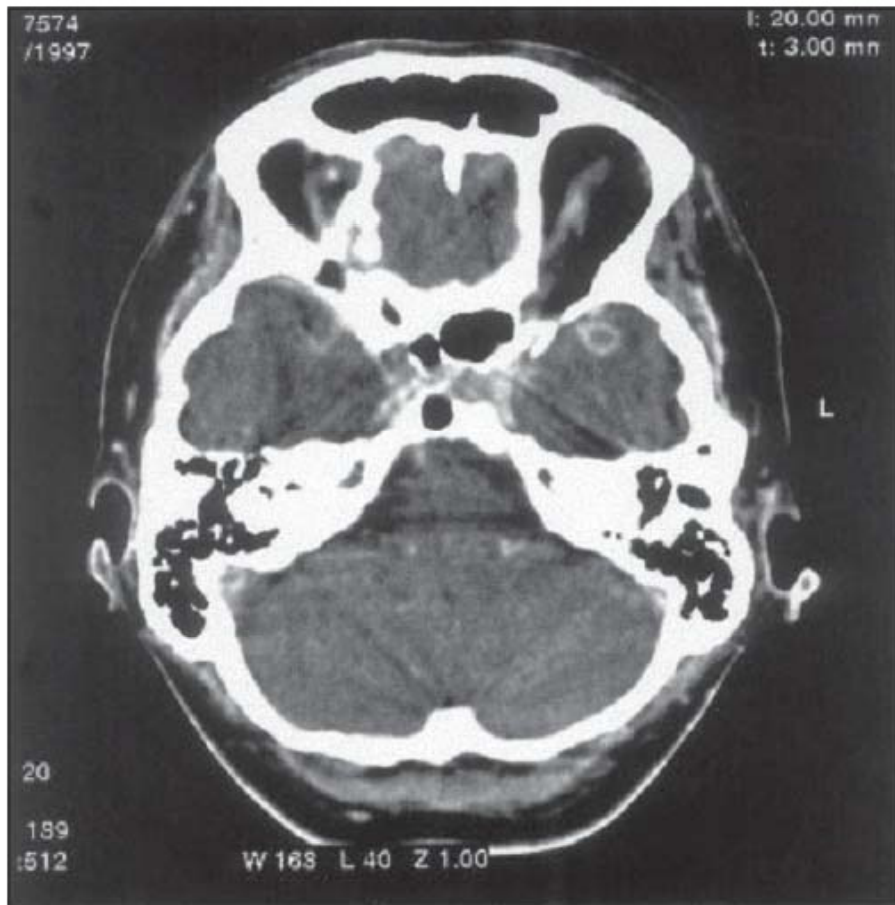
of historical significance

Imaging

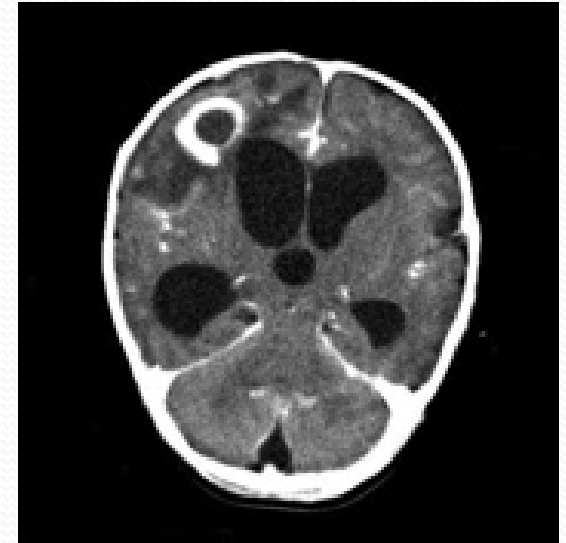
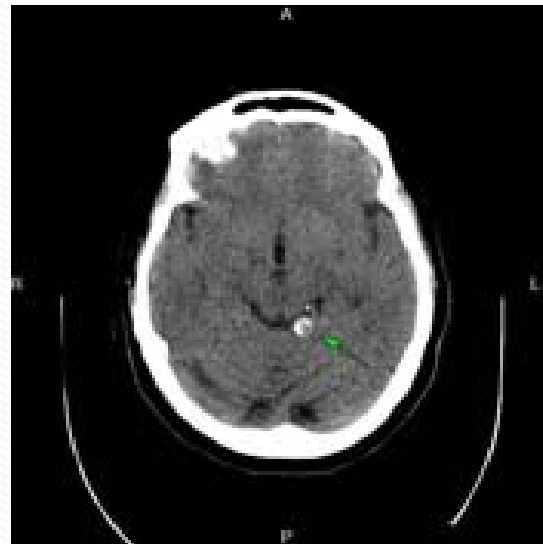
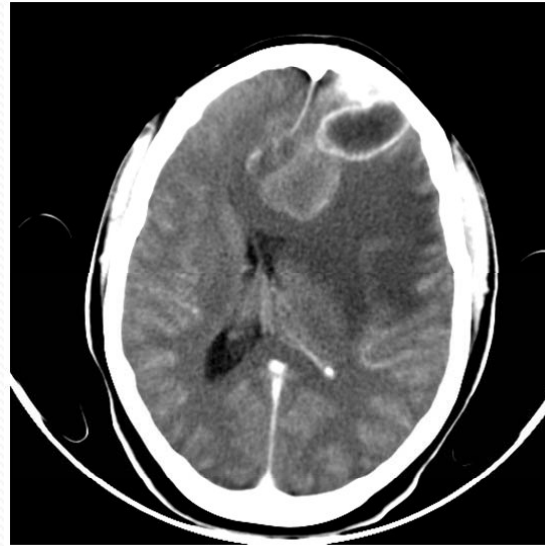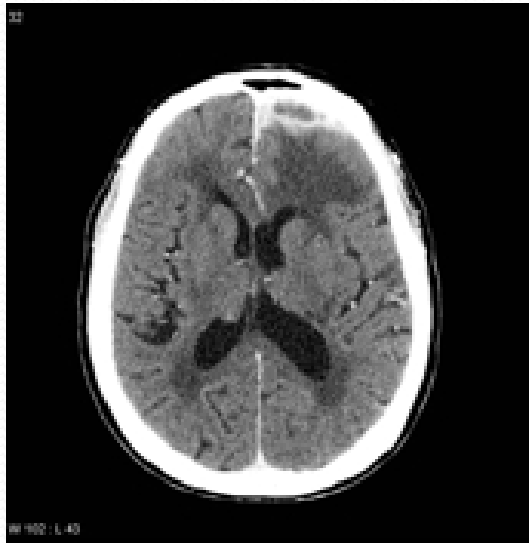- Tuberculoma
 - Typically cortical and subcortical
 - Multiple in 10-35%
 - Millitary rare (children)
- Meningitis (commonest form of CNS TB)
 - Isolated meningitis is rare (5% in children)
 - Basal cisterns

Imaging (CT tuberculoma)

- ▶ Cerebritis: hypodense areas
- ▶ Perilesional oedema out of proportion
- ▶ Early tuberculoma: iso to slightly hyper dense , ring enhancement
- ▶ Evolved : well delineated ring enhancing mass, target sign (central enhancement or calcification)
- ▶ Healed: often calcify
- ▶ Manifestations
 - Small disc/ rings
 - Large rings with central lucency
 - Large nodular mass with irregular outline
 - Multiple lesions in 15-20%

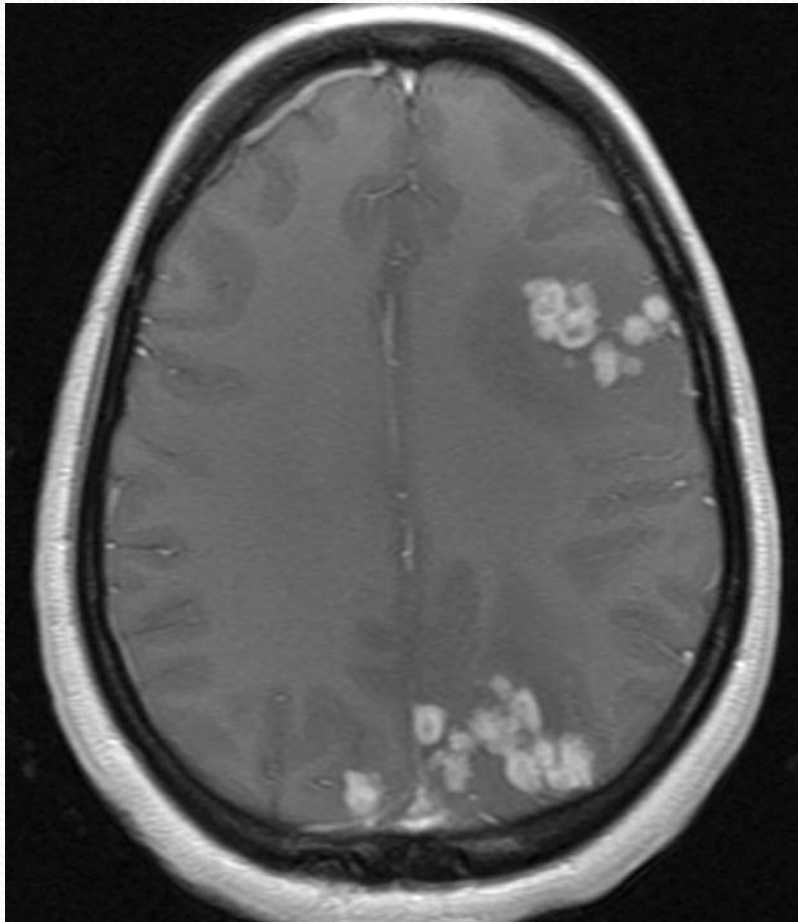


Caseating tuberculosis granuloma involving the left temporal lobe. CECT shows a rim-enhancing lesion in the left temporal lobe consistent with a caseating tuberculosis granuloma

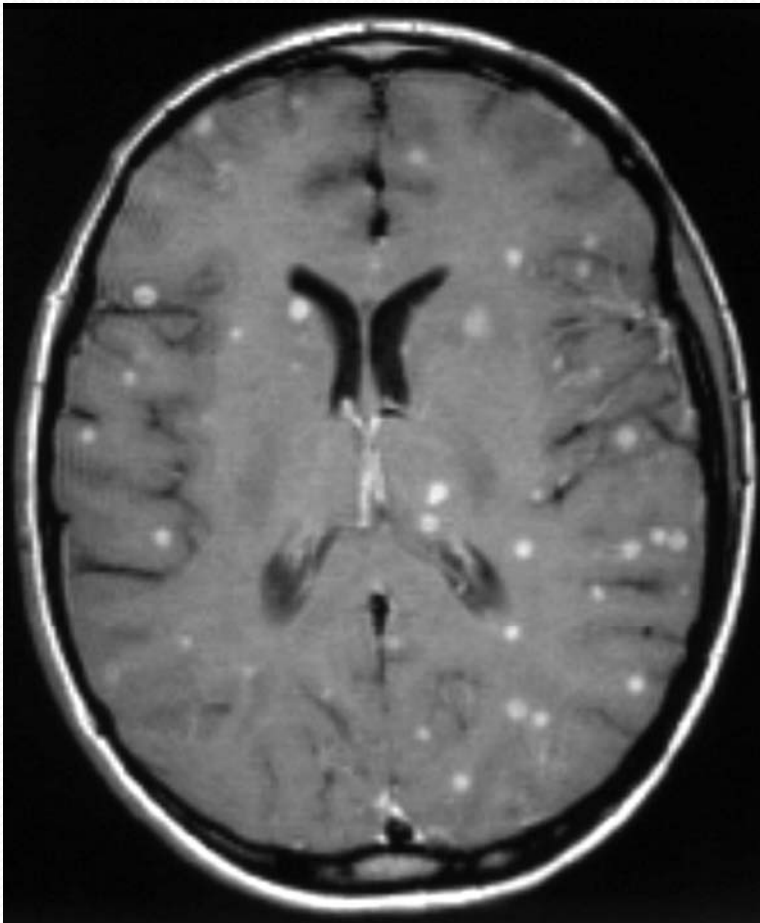


Imaging (MRI tuberculoma)

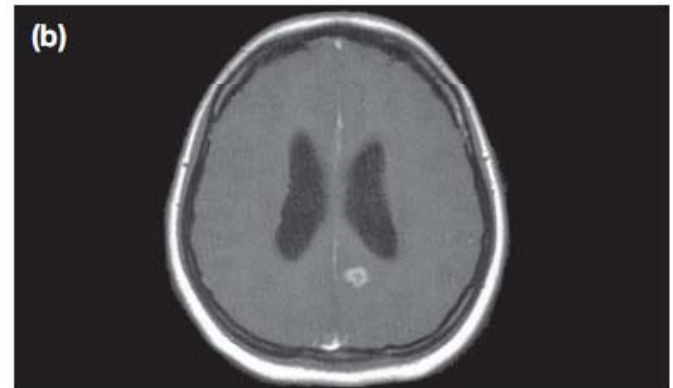
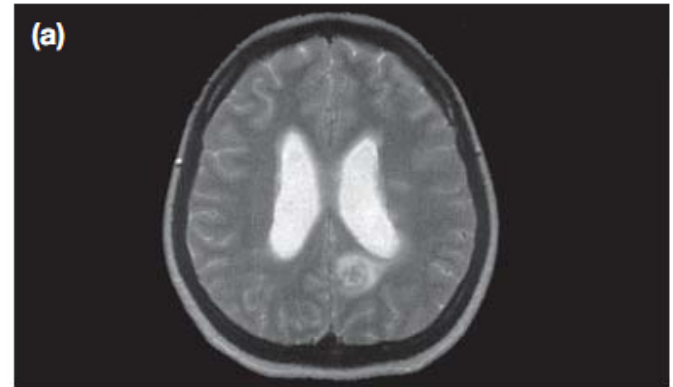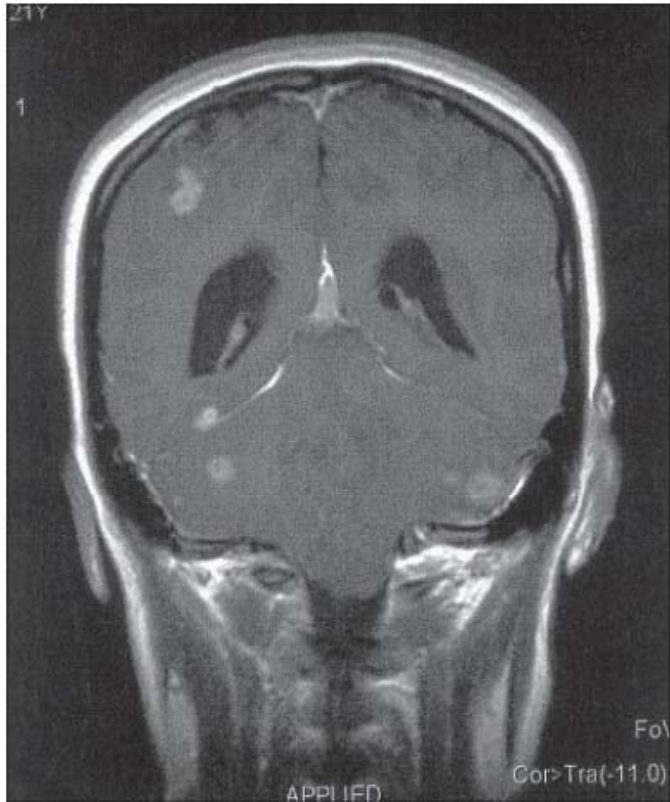
- T₁ : isointense
- T₂: central hyper with hypo ring
- Marked thin rim enhancement
- Hypo on T₂: fibrosis, gliosis, macrophage infiltration

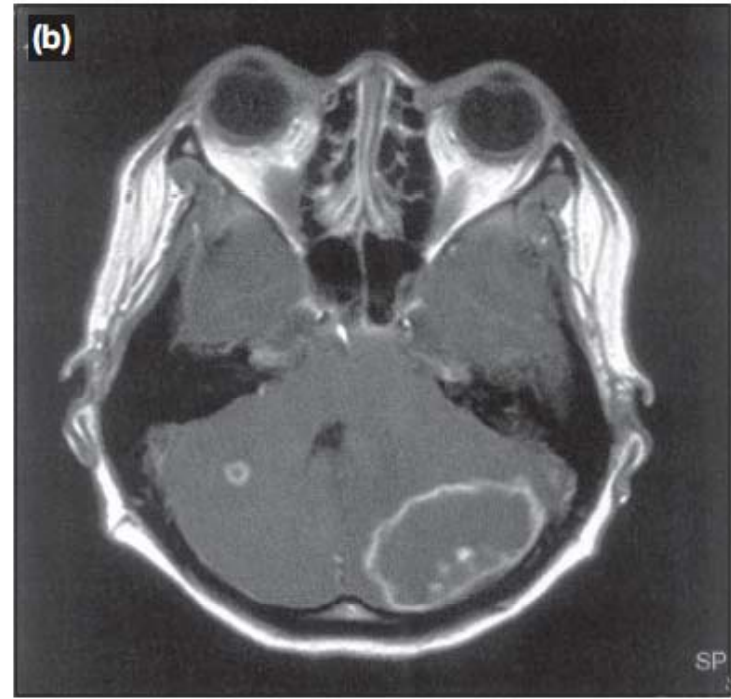
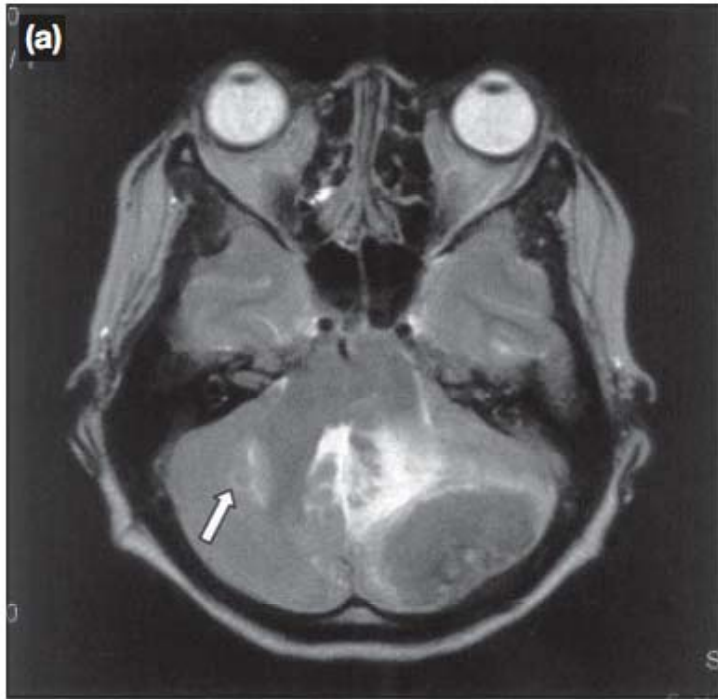


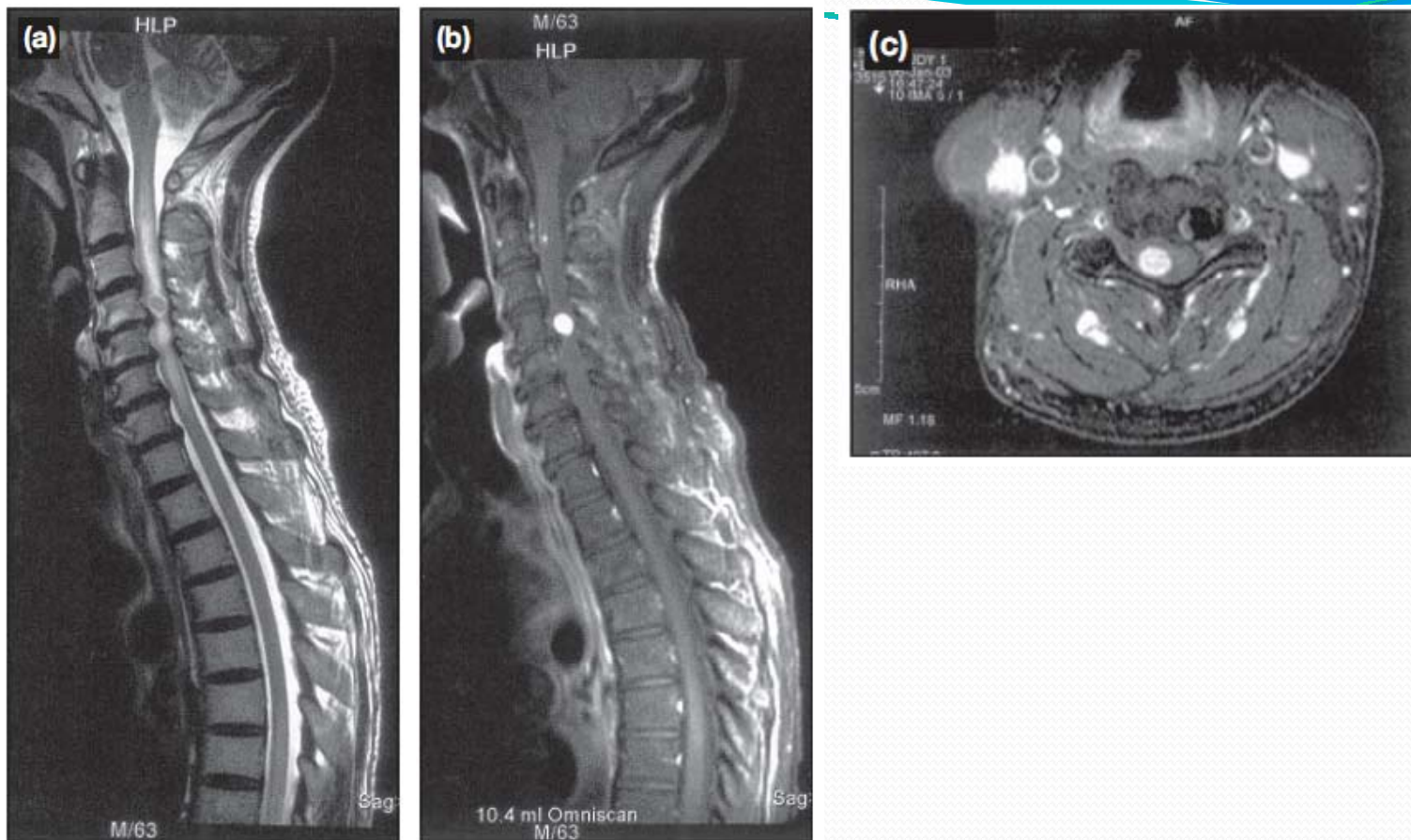
Pararenchymal tuberculosis. contrast-enhanced T1-weighted MR image demonstrates multiple enhancing caseating and non-caseating tuberculomas, predominantly within the left frontal and parietal lobes



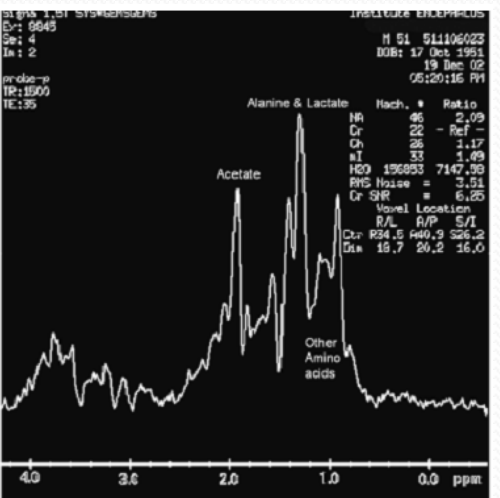
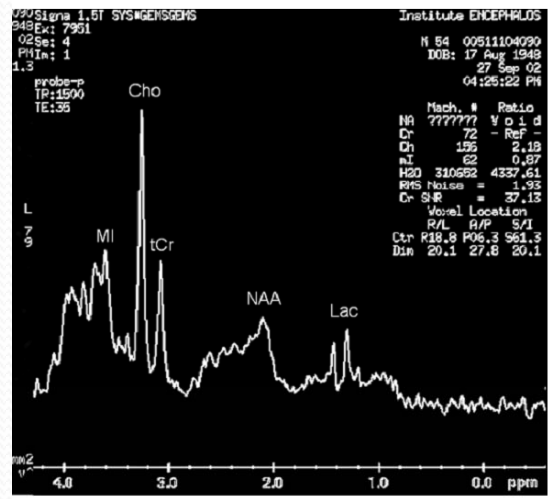
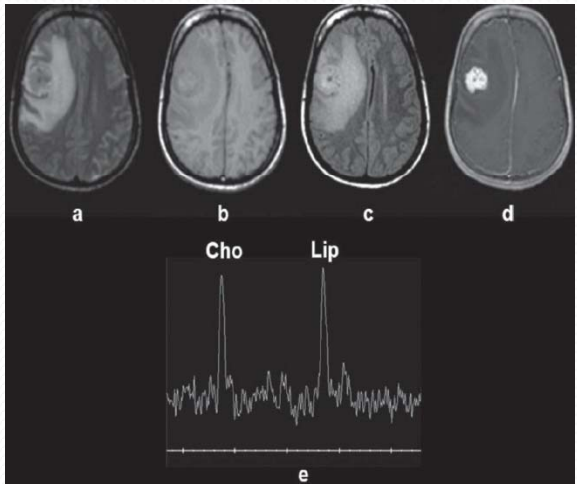
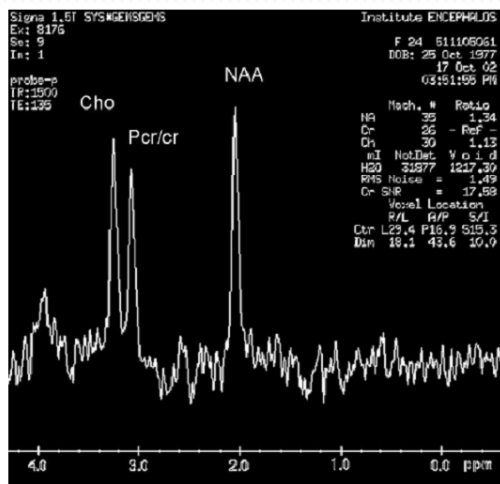
Milliary CNS tuberculosis. Axial contrast-enhanced T1-weighted MR image shows multiple small high-signal-intensity foci within both cerebral hemispheres







(a) Sagittal T2- hyperintensity in the cervical spinal cord extending from C2 to C7. A hypointense nodule representing the granuloma is noted at the C4 level.
 (b) Sagittal T1 & (c) axial T1- with fat suppression after contrast reveal an area of solid nodular enhancement representing non-caseating tuberculosis granuloma of the spinal cord. A smaller enhancing granuloma is also noted at the C2 level on the sagittal image



- decrease in NAA/Cr
- slight decrease in NAA/Cho
- lipid-lactate peaks are usually elevated (86%)

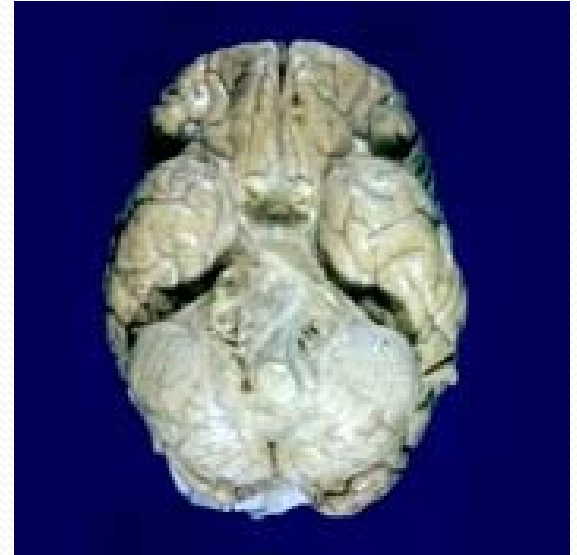	CT	MRI
Noncaseating granuloma	NECT: hypo-/isodense CECT: homogenous enhancement	T1WI: low SI T2WI: high SI T1WI Gd: homogenous enhancement
Caseating granuloma with a solid center	CECT: heterogenous enhancement centrally Ring enhancement of the capsule	T1WI: low/intermediate SI T2WI: intermediate/low SI T1WI Gd: rim enhancement
Caseating granuloma with a liquid center	NECT: hypodense CECT: rim enhancement	T1WI: hypointense SI T2WI: hyperintense SI + rim hypo T1WI Gd: rim enhancement

A. Bernaerts, F. M. Vanhoenacker Tuberculosis of the central nervous system: overview of neuroradiological findings. Eur Radiol (2003) 13:1876–1890

Imaging (meningitis)

- Active
- Sequelae
 - Hydrocephalus
 - Ischemia and infarction
 - Medial lenticulostriate
 - Thalamoperforating
 - Cortex 25%
 - Bilateral 70%
 - Atrophy
 - Calcification

} 75%



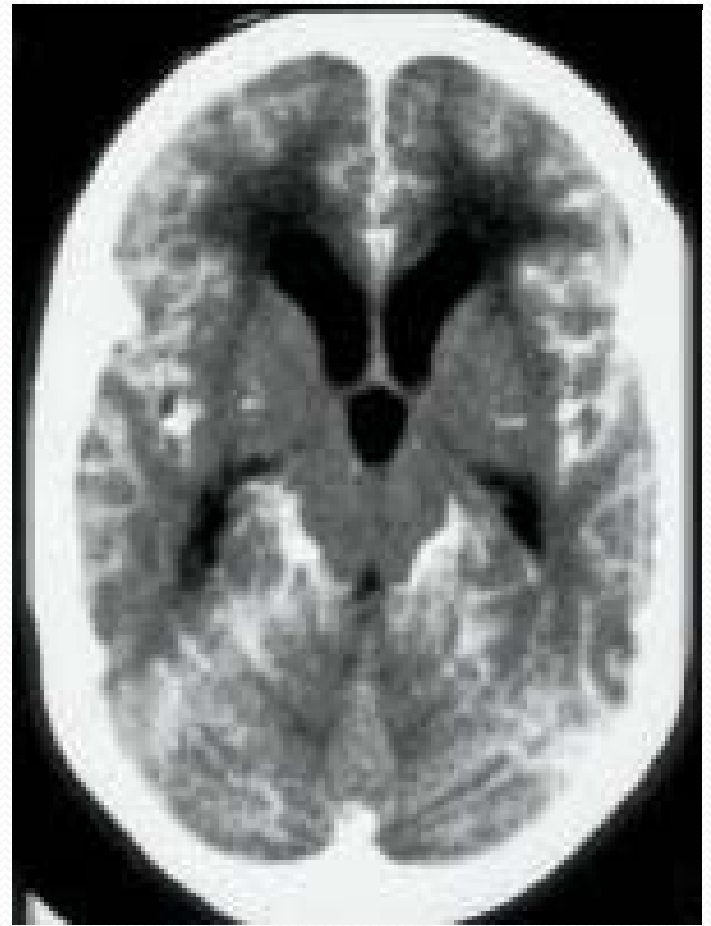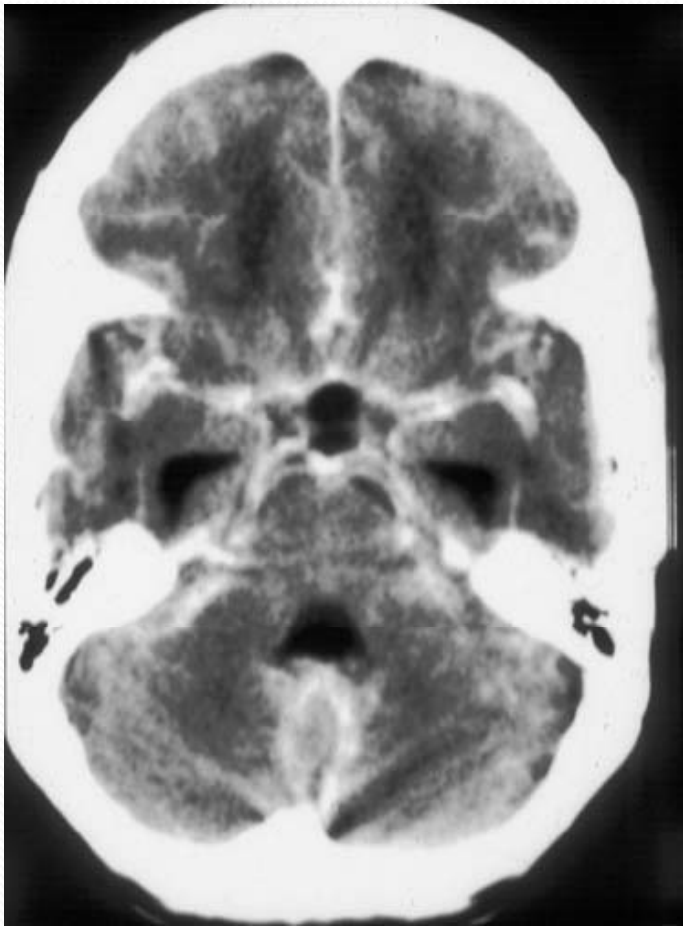
Imaging (CT meningitis)

▶ NCCT:

- scans may be normal
- Obliteration of basal cisterns by hypo/ iso dense exudate
- en plaque dural thickening
- Popcorn calcification
- Hydrocephalus
- Sequelae of chronic meningitis
 - Infarcts

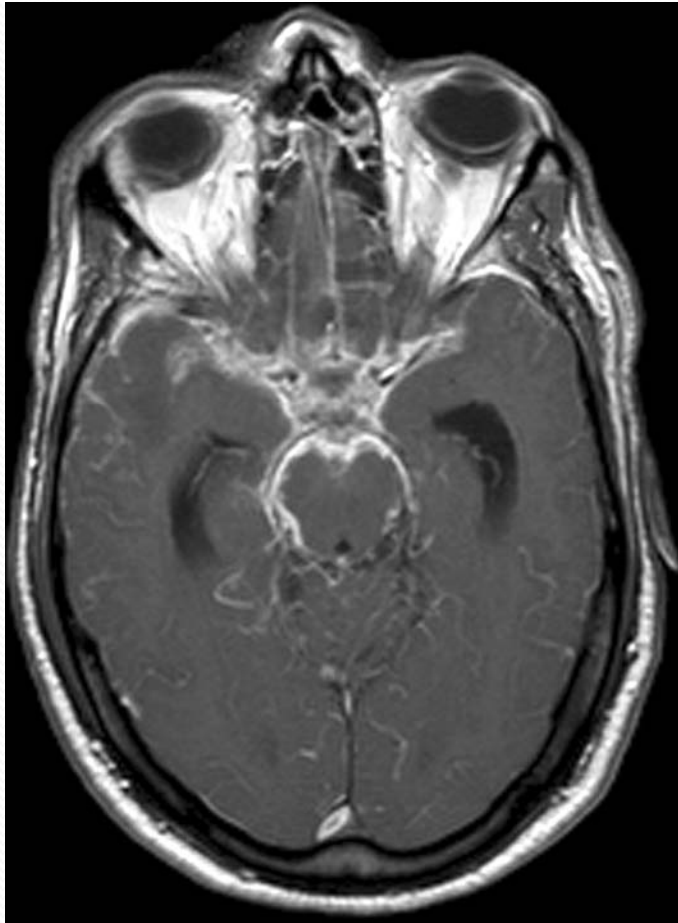
▶ CECT:

- Abnormal meningeal enhancement (may persist)
- Leptomeningeal enhancement sylvian fissures, tentorium
- Granulomas in the basal meninges
- Ependymitis

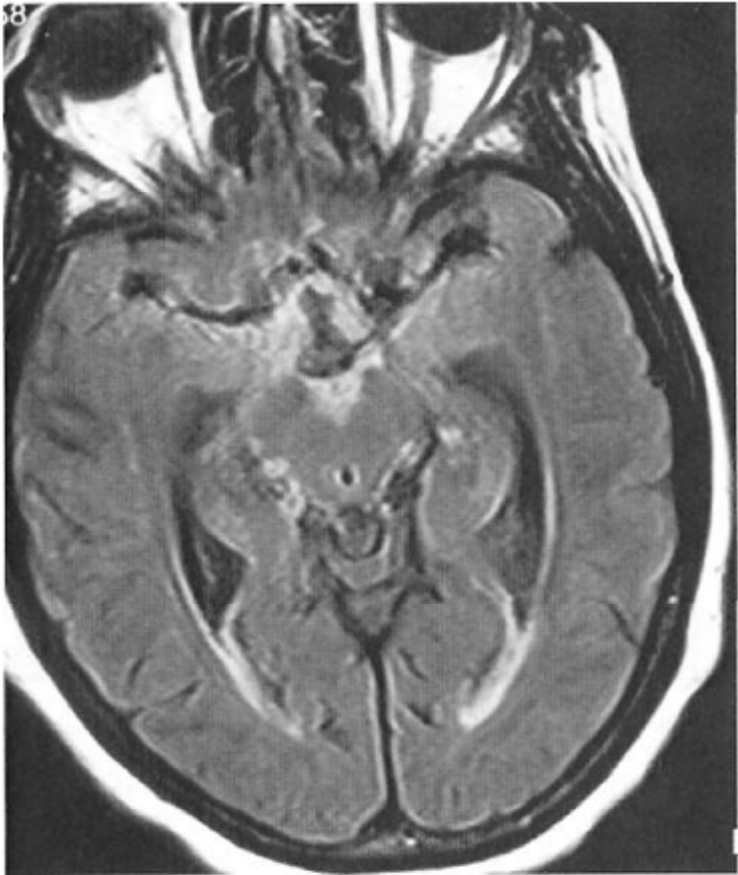


Imaging (MRI meningitis)

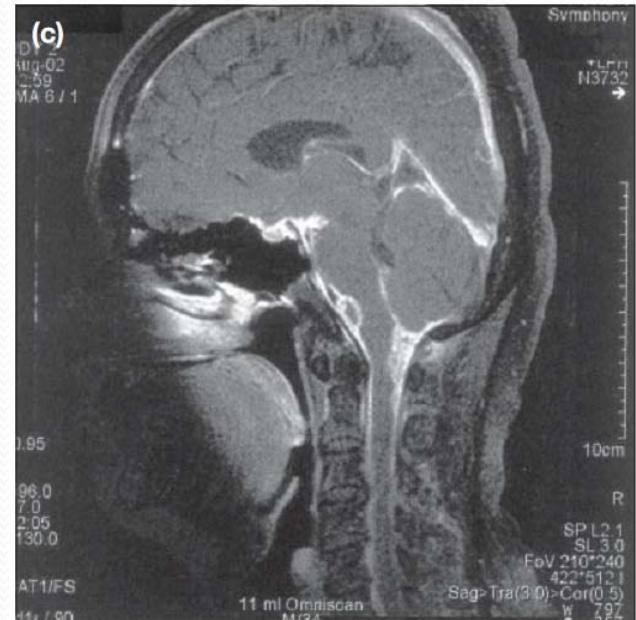
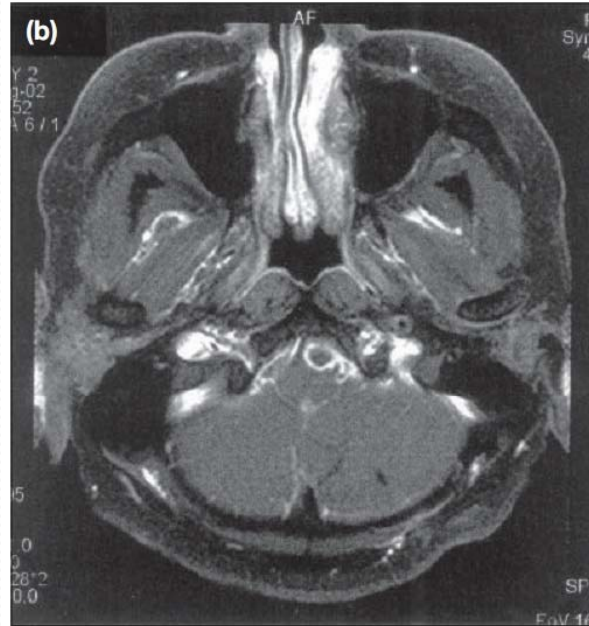
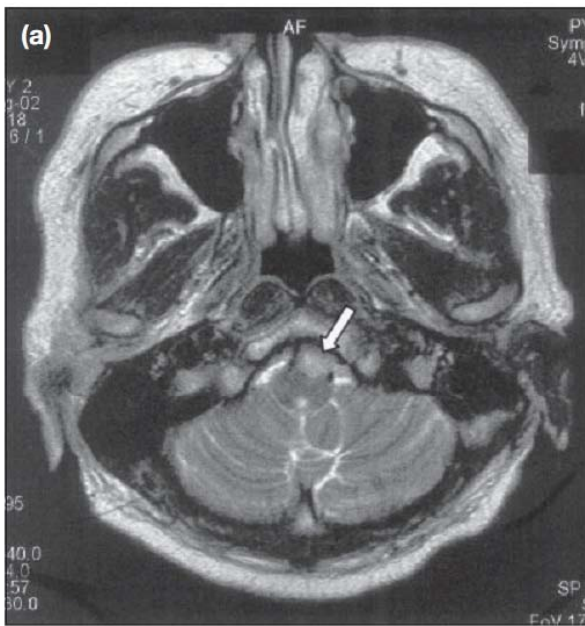
- Unenhanced scan: does not show active meningitis
 - Spine
 - CSF loculations
 - Obliteration of arachnoid space
 - Loss of cord outline in cervicodorsal cord
 - Thickening and clumping of roots in the lumbar cord
- Contrast T₁ : basal meningeal enhancement
 - spine
 - Linear enhancement of cord/ roots



Tuberculous meningitis. Axial contrast-enhanced T1-weighted magnetic resonance (MR) image shows florid meningeal enhancement that is most pronounced within the basal cisterns

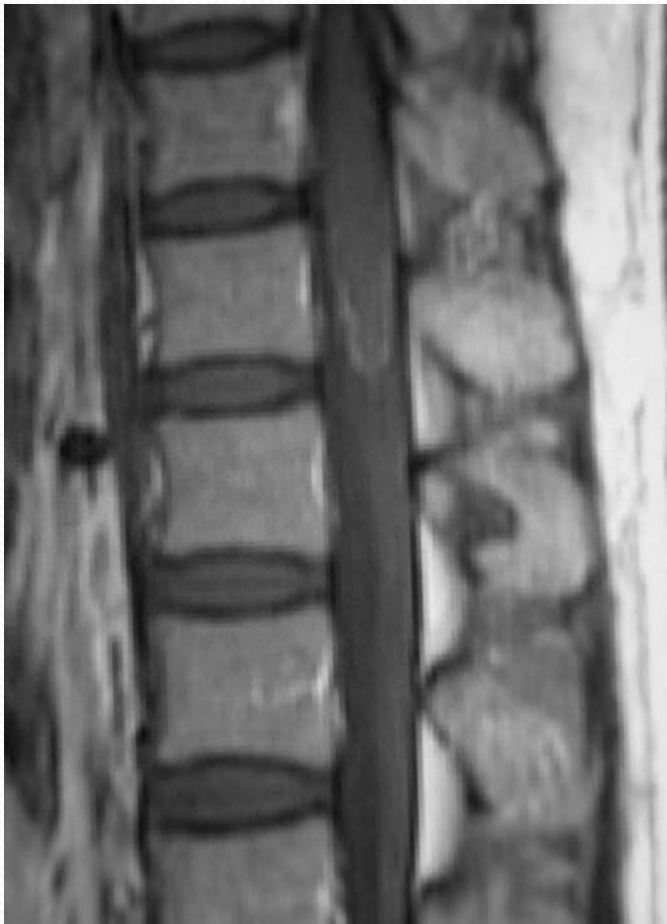

Tubercular meningitis. Axial FLAIR-MRI showing marked hyperintensity of the basal cisterns and prominent temporal horns in a patient with mild communicating hydrocephalus

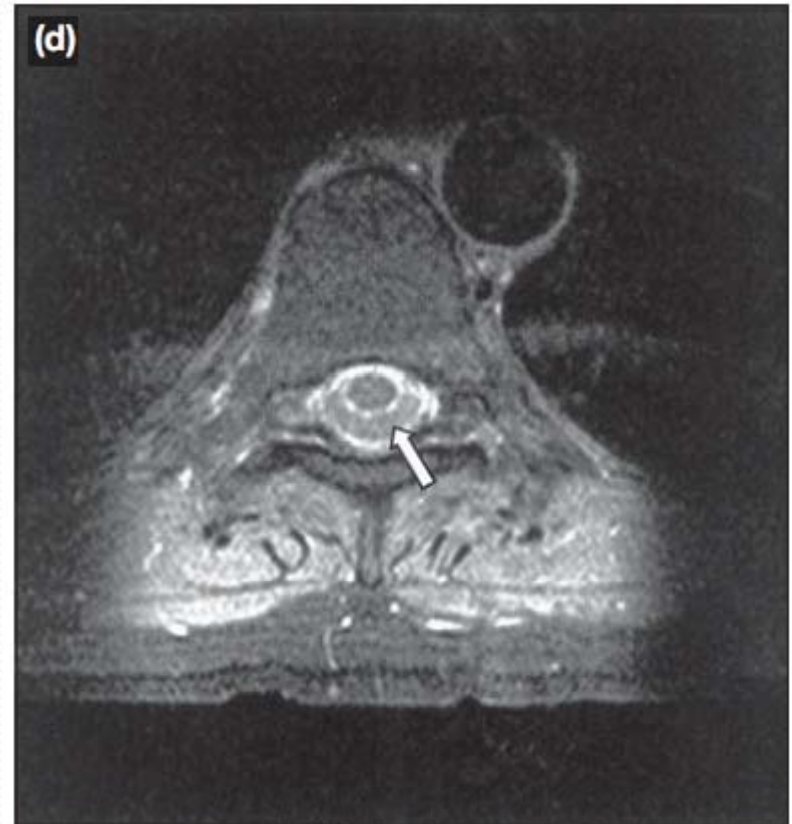
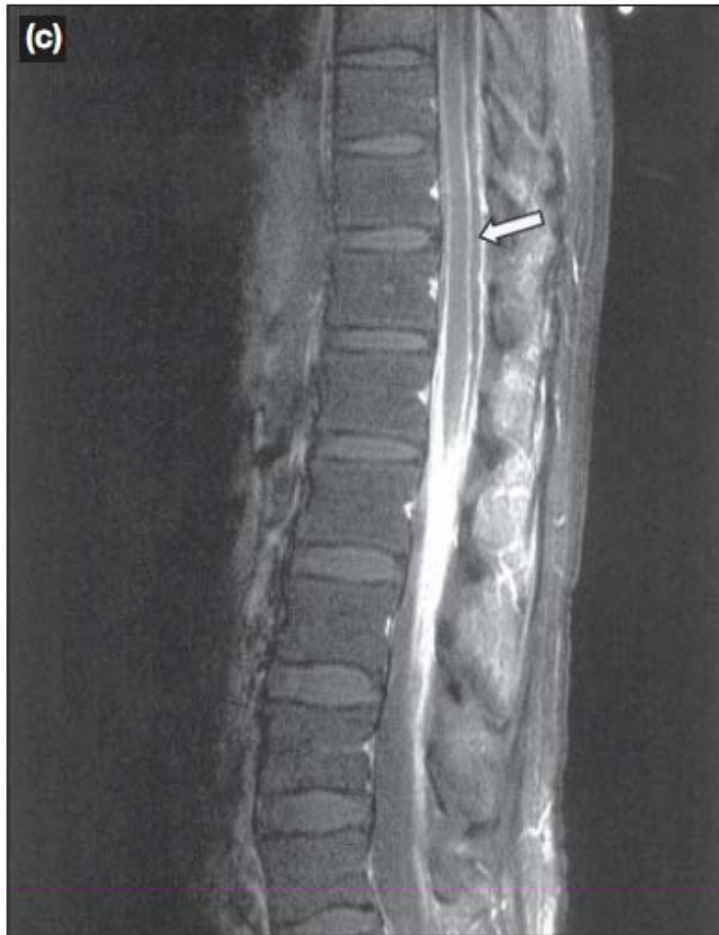

Caseating dural /epidural tuberculosis granuloma or abscess

- a) Axial T2– nodular hyperintensity posterior to the clivus and anterior to the medulla (arrow).
- b) Axial T1 contrast– dural/epidural rim enhancement suggestive of caseating tuberculosis granuloma or abscess.
- c) Sagittal enhanced T1– the caseating dural/epidural tuberculosis granuloma or abscess posterior to the clivus. Abnormal meningeal enhancement is present



Spinal tuberculous meningitis. Sagittal gadolinium-enhanced T1-weighted MR image of the thoracic spine demonstrates irregular, linear, nodular meningeal enhancement



Enhanced T1-weighted magnetic resonance imaging with fat suppression show intense enhancement of the subarachnoid space indicating arachnoiditis

Tuberculous pachymeningitis

- ▶ Rare
- ▶ Common sites of involvement are cavernous sinus, floor of middle cranial fossa and tentorium.
- ▶ **Radiographic features**
- ▶ **CT**
 - hyperattenuating solid plaque like densities (calcification may be seen)
- ▶ **MRI**
 - T₁ : hypo intense thickened duramater.
 - T₂ : hypo intense thickened meninges.
 - T₁ C+ (GAD) : intense homogenous enhancement of thickened meninges.

Management

- Medical therapy
- Surgery
 - indications
 - Vision or life threatened by mass effect
 - Failure of response to medical therapy
 - Paradoxical increase in lesion size with therapy
 - Diagnosis in doubt

Medical therapy

Drug	Recommended dose			
	Daily		3 times per week	
	Dose and range (mg/kg body weight)	Maximum (mg)	Dose and range (mg/kg body weight)	Daily maximum (mg)
Isoniazid	5 (4–6)	300	10 (8–12)	900
Rifampicin	10 (8–12)	600	10 (8–12)	600
Pyrazinamide	25 (20–30)	–	35 (30–40)	–
Ethambutol	15 (15–20)	–	30 (25–35)	–
Streptomycin ^a	15 (12–18)		15 (12–18)	1000

^a Patients aged over 60 years may not be able to tolerate more than 500–750 mg daily, so some guidelines recommend reduction of the dose to 10 mg/kg per day in patients in this age group (2). Patients weighing less than 50 kg may not tolerate doses above 500–750 mg daily (*WHO Model Formulary 2008*, www.who.int/selection_medicines/list/en/).

Intensive phase treatment	Continuation phase
2 months of HRZE ^a	4 months of HR

^a WHO no longer recommends omission of ethambutol during the intensive phase of treatment for patients with non-cavitary, smear-negative PTB or EPTB who are known to be HIV-negative. In tuberculous meningitis, ethambutol should be replaced by streptomycin.

H = isoniazid, R = rifampicin, Z = pyrazinamide, E = ethambutol, S = streptomycin

WHO recommendations

Pulmonary and extrapulmonary disease should be treated with the same regimens (see Chapter 3).¹ Note that some experts recommend 9–12 months of treatment for TB meningitis (2, 3) given the serious risk of disability and mortality, and 9 months of treatment for TB of bones or joints because of the difficulties of assessing treatment response (3). Unless drug resistance is suspected, adjuvant corticosteroid treatment is recommended for TB meningitis and pericarditis (1–4). In tuberculous meningitis, ethambutol should be replaced by streptomycin.

2. National Collaborating Centre for Chronic Conditions. *Tuberculosis: clinical diagnosis and management of tuberculosis, and measures for its prevention and control*. London, Royal College of Physicians, NICE (National Institute for Health and Clinical Excellence), 2006.
3. American Thoracic Society, CDC, Infectious Diseases Society of America. Treatment of tuberculosis. *Morbidity and Mortality Weekly Report: Recommendations and Reports*, 2003, 52(RR-11):1–77.

WHO Treatment of tuberculosis: guidelines – 4th ed.

Duration of treatment

6 months

van Loenhout-Rooyackers JH, Keyser A, Laheij RJ, Verbeek AL, van der Meer JW. Tuberculous meningitis: Is a 6-month treatment regimen sufficient? *Int J Tuberc Lung Dis* 2001;5:128-35.

12 months

Thwaites GE, Hein TT. Tuberculous meningitis: Many questions, too few answers. *Lancet Neurol* 2005;4:160-70

18 months or Longer

Santosh Isac Poonnoose, Vedantam Rajashekhar: Rate of Resolution of histologically verified intracranial tuberculomas. *Neurosurgery* 53:873–879, 2003

Treatment

Rate of radiological resolution of intracranial tuberculoma

Series	duration of ATT	residual lesions %
Wang 1996 (16)	6	20
Rajeshwari 1995 (6)	9	12
Awada 1998 (2)	12	0
Poonnoose 2003 (28)	18	69.2

Santosh Isac Poonnoose, Vedantam Rajashekhar: Rate of Resolution of histologically verified intracranial tuberculomas. Neurosurgery 53:873–879, 2003

Medical management

- 4 drugs x 3-4 months
- 2 drugs x 14-16 months occasionally longer
- Regression of size from 4-6 weeks
- Most resolve in 12-14 months

R Patir, R Bhatia, Tandon PN. Surgical management of tuberculous infections of the nervous system. Schmidek and Sweet operative neurosurgical techniques 5th edition; 1617-1631

- AED to continue
- INH blocks phenytoin metabolism
- Steroids in all irrespective of age and stage

Prasad K, Singh MB. Corticosteroids for managing tuberculous meningitis. Cochrane Database Syst Rev 2008;1:CD002244.

Resistant tuberculosis

- MDR : resistant to INH and Rifampicin
- EDR/ XDR : MDR + resistance to Quinolones and injectable second line drugs

Second line drugs

Group	Drugs (abbreviations)
Group 1: First-line oral agents	<ul style="list-style-type: none"> • pyrazinamide (Z) • ethambutol (E) • rifabutin (Rfb)
Group 2: Injectable agents	<ul style="list-style-type: none"> • kanamycin (Km) • amikacin (Am) • capreomycin (Cm) • streptomycin (S)
Group 3: Fluoroquinolones	<ul style="list-style-type: none"> • levofloxacin (Lfx) • moxifloxacin (Mfx) • ofloxacin (Ofx)
Group 4: Oral bacteriostatic second-line agents	<ul style="list-style-type: none"> • para-aminosalicylic acid (PAS) • cycloserine (Cs) • terizidone (Trd) • ethionamide (Eto) • protionamide (Pto)
Group 5: Agents with unclear role in treatment of drug resistant-TB	<ul style="list-style-type: none"> • clofazimine (Cfz) • linezolid (Lzd) • amoxicillin/clavulanate (Amx/Clv) • thioacetazone (Thz) • imipenem/cilastatin (Ipm/Cln) • high-dose isoniazid (high-dose H)^b • clarithromycin (Clr)

- Use any of the first-line oral agents (Group 1) that are likely to be effective.
- Use an effective aminoglycoside or polypeptide by injection (Group 2).^b
- Use a fluoroquinolone (Group 3).
- Use the remaining Group 4 drugs to complete a regimen of at least four effective drugs.
- For regimens with fewer than four effective drugs, consider adding two Group 5 drugs. The total number of drugs will depend on the degree of uncertainty, and regimens often contain five to seven.

Use at least 4 drugs

Surgery

- Severe elevation of ICP
- Threatening life or vision
- Do not respond to drugs clinically/ radiologically
- Diagnosis in doubt
- Obstructive hydrocephalus

R Patir, R Bhatia, Tandon PN. Surgical management of tuberculous infections of the nervous system. Schmidek and Sweet operative neurosurgical techniques 5th edition; 1617-1631

- Aim diagnosis/ relieve pressure

Surgical management

- Biopsy of the mass lesion
- Hydrocephalus
 - Communicating (commoner)
 - Non communicating

Surgery principles

- Non eloquent areas total excision (small lesion)
- Subtotal/ partial excision (large lesion/ eloquent cortex)
- Conservative excision around vital structures
- Evacuation of central liquifactive portion in deep seated lesions
- Residual lesions may respond to medical therapy
 - R Patir, R Bhatia, Tandon PN. Surgical management of tuberculous infections of the nervous system. Schmidek and Sweet operative neurosurgical techniques 5th edition; 1617-1631
- Hydrocephalus

MRC Grading for hydrocephalus

Stage	
1	Fully conscious, no paresis
2	Decreased level of consciousness, localizing pain
3	Deeply comatose \pm gross paresis

Grading for hydrocephalus

Grade	
I	Headache, vomiting, fever \pm neck stiffness No neurological deficit Normal sensorium
II	Normal sensorium Neurological deficit present
III	Altered sensorium but easily arousable Dense neurological deficit may or may not be present
IV	Deeply comatose Decerebrate or decorticate posturing

From Palur *et al.*

Vellore grading

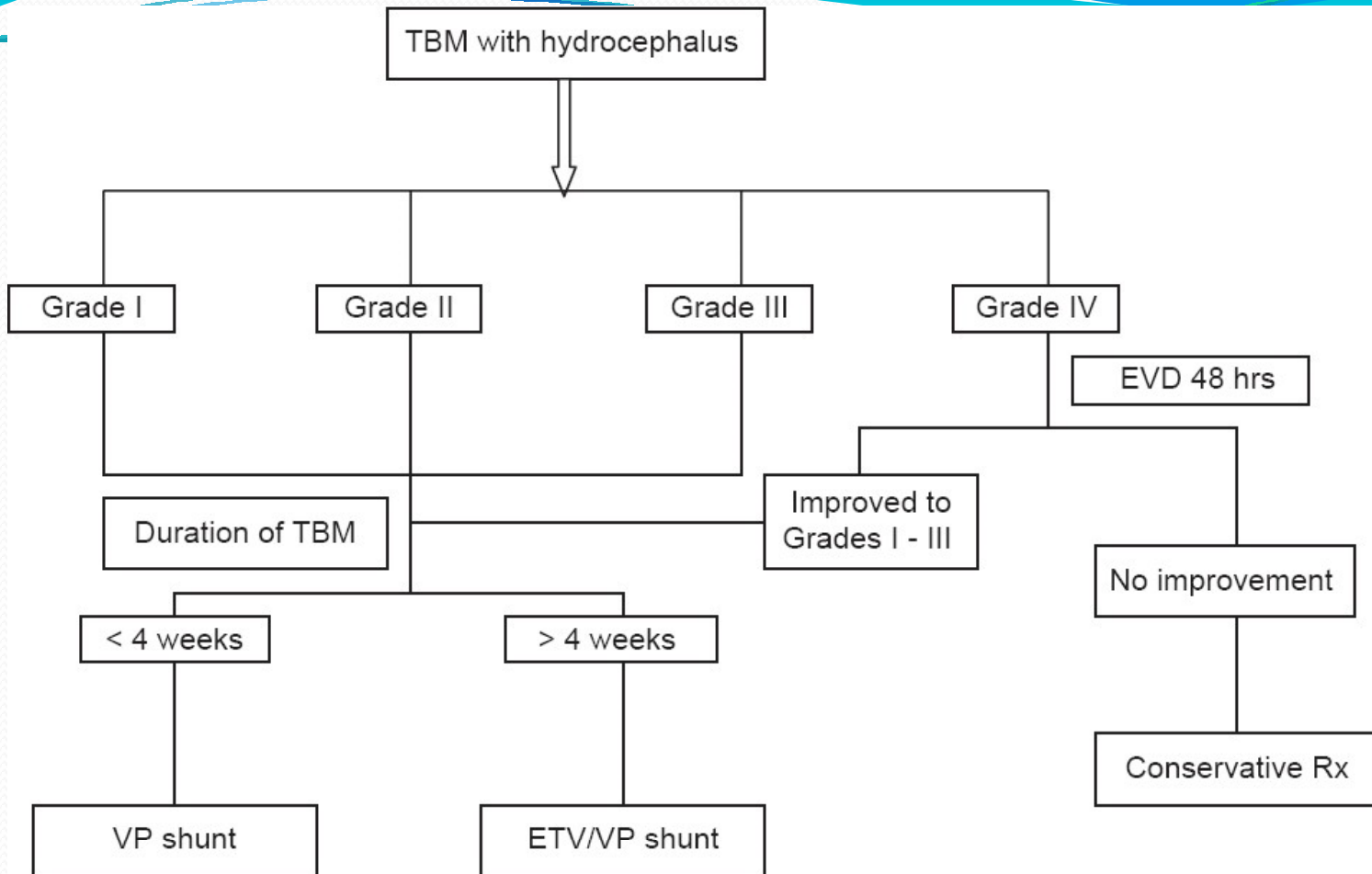
Grade	
I	GCS 15 Headache, vomiting, fever \pm neck stiffness No neurological deficit
II	GCS 15 Neurological deficit present
III	GCS 9-14 Neurological deficit may or may not be present
IV	GCS 3-8 Neurological deficit may or may not be present

From Mathew *et al.* GCS - Glasgow coma score

Modified Vellore grading

Palur R, Rajshekhar V, Chandy MJ, Joseph T, Abraham J. Shunt surgery for hydrocephalous in tubercular meningitis: A long-term follow-up study. J Neurosurg 1991;74:64-9

Mathew JM, Rajshekhar V, Chandy MJ. Shunt surgery for poor grade patients with tuberculous meningitis and hydrocephalus: Effect of response to external ventricular drainage and other factors on long-term outcome. J Neurol Neurosurg Psychiatry 1998;65:115-8



Rajshekhar V. Management of hydrocephalus in patients with tuberculous meningitis. *Neurol India* 2009;57:368-74

Hydrocephalus

- Inevitable in those who survive 4-6 weeks
- Mortality 20-100%
- Grade at admission significant
- Early shunt for grade I,II

- ETV

- 73.1% success rate for ETV in TBM with hydrocephalus

- *A chugh, M hussain et al. Surgical outcome of tuberculous meningitis hydrocephalus treated by endoscopic third ventriculostomy: prognostic factors and postoperative neuroimaging for functional assessment of ventriculostomy: J Neurosurg Pediatrics 3:000-000, 2009*

- Endovascular revascularization for ischemia

- STA MCA bypass

- The left superficial temporal artery-MCA bypass was found to be capable of preventing new ischemic events in the 21-month follow-up period

- *Martin misch, Ulrich- wilhelm et al. Prevention of secondary ischemic events by superficial temporal artery-middle cerebral artery bypass surgery after tuberculosis-induced vasculopathy in a 5-year-old child: Neurosurg Pediatrics 6:000-000, 2010*

AIIMS DATA (1975-1992)

SUPRATENTORIAL	78
PARIETAL	28
FRONTAL	26
TEMPORAL	15
BG / THALAMUS	4
SELAR/SUPRASELLAR	4
ORBITAL FISSURE	1
INFRATENTORIAL	50
CEREBELLUM	44
CP ANGLE	3
TENTORIUM	1
BRAINSTEM	2



Thank you